

Cytologic Types of Squamous Carcinoma in Situ of the Uterine Cervix

Hiromitsu YASUMATSU

*Department of Clinical Pathology, Toyo-Kogyo
Hospital, Hiroshima, Japan.*

*Guest Lecturer; College of Medical Technology,
Yamaguchi University School of Medicine, Ube,
Japan.*

(Received September 26, 1972)

INTRODUCTION

Squamous carcinoma in situ of the uterine cervix is an alteration of the surface epithelium which histologically resembles cervix cancer without evidence of invasion of the underlying fibromuscular stroma.³ In general, the cells exfoliated from the lesion demonstrate abnormal characteristics including a large nuclear-cytoplasmic ratio, and various degrees of nuclear chromatin abnormalities. Many investigators, however, have recognized that there are considerable variations in the cytologic or histologic patterns of squamous carcinoma in situ.¹⁻³⁾⁵⁾⁸⁾¹⁰⁾¹⁴⁾

The purpose of this investigation was to describe the cells found in squamous carcinoma in situ of the uterine cervix and to provide a detailed morphological system of classification of those cells.

MATERIALS AND METHODS

Thirty cases of histologically-proven squamous carcinoma in situ of the uterine cervix were selected from the cytology files at Los Angeles County-University of Southern California Medical Center. The smears were screened and the cell morphology was interpreted on the basis of the criteria of Gard et al.² According to Gard there are seven types of squamous carcinoma in situ cells. His "third type cell" and "clustered cancer cell" display generally the size of an inner basal cell and round or oval, and the nuclear chromatin shows alteration in structure. Gard's "large non-keratinizing cell" has usually a round or oval nucleus with a finely granular chromatin pattern. His "Keratinizing cancer cell" has an irregular form, and nucleus shows marked hyperchromasia. Gard's "small malignant cell" is small in size and has a coarsely granular chromatin pattern and a high N/C ratio. His "fiber cell" and "undifferentiated cancer cell" display spindle shaped nucleus with eosinophilic cytoplasm, and marked variation in size and shape with

indistinct cytoplasm, respectively. The characteristics and relative number of non-neoplastic elements (inflammatory cells, bacteria flora, erythrocytes and trichomonas) were also studied.

RESULTS

The age of patients in this study ranged from 22 to 65 years with a mean age of 40.1 years. All 30 patients had some form of inflammatory response identifiable in the Papanicolaou smear. In general, the predominant inflammatory cell was a degenerated polymorphonuclear leukocyte, although a few lymphocytes, histiocytes and eosinophils were present. Erythrocytes were identified in 12, or 33.3 per cent of the patients. Usually the erythrocytes were degenerated and the blood appeared in a fibrinated form. In the large cell type of carcinoma in situ erythrocytes were less common than in other types. Abnormal bacterial flora was found in 66.6 per cent of the cases. Cocci and rods predominated. In five cases Doderlein bacilli were identified. *Candida* species was found in two cases. *Trichomonas vaginalis* was found in five cases, or 16.6 per cent of the cases.

The number of malignant cells in each case was identified as: few, moderate or many. Twenty-three of the cases, or 76 per cent had moderate or many cancer cells; 7 cases had few malignant cells. Dysplastic elements were found in 27 cases, or 77.1 per cent of the cases. The number of such cells varied from case to case.

Several tumor cell types were observed in squamous carcinoma in situ of the uterine cervix.

Small type cells: These cells were usually smaller than third type cells and were isodiametric. The cytoplasm was usually cyanophilic and had a poorly defined cell border. The cell characteristically appeared in clusters, showing syncytial arrangement. The nuclei generally had a hyperchromatic and coarse granular chromatin pattern which suggested "impending prophase." When this small type cells were observed in smears from patients over 50 years of age, they were more loosely arranged than when they were found in patients under 50 years of age. No prominent nucleoli were identified in the small type, carcinoma-in-situ cells. Chromocenters were seen occasionally. (Fig. 2)

Large type cells: The individual cells were almost identical to "third type cells". These cells with round or oval nuclei characteristically appeared in clusters, showing syncytial arrangement. The cytoplasm was usually cyanophilic and had a poorly defined cell border as in small type cells. The nucleus ordinarily had a finely granular chromatin pattern and the "impending prophase" picture was found uncommonly. Nucleoli were less common than in the small type cells. (Fig. 1)

Third type cells: These cells were round or oval, generally the size of an inner basal cell, and isodiametric. The cytoplasmic staining reaction was usually cyanophilic. The cytoplasm had a relatively well defined cell border. The nucleus occupied a relatively large area with the distance from the nuclear border to the cellular border being less than the maximum diameter of the nucleus.¹⁾ Nuclear chromatin showed various degrees of clumping. Nucleoli very rarely were noted. The third type cells appeared singly or in groups with a sheet-like or loose arrangement. (Fig. 3)

Large non-keratinizing cells: These cells were generally, though not always, smaller than the third type cells. They had a slightly increased N/C ratio and characteristically appeared in clusters. The cytoplasm was blue to colorless. The cells were usually isodiametric although at times slight irregularity was evident. The nucleus generally had a coarsely granular chromatin pattern, showing a poorly defined cellular border. Nucleoli were conspicuous on occasion. Prominent chromocenters were common. These cells appeared to be similar to cells of glandular origin. (Fig. 4)

Small cancer cells: These cells were round or oval and ordinarily appeared singly. They usually were smaller than small type cells. Occasionally they appeared in non-cohesive groups, showing variation in size. The nucleus occupied a relatively large cellular area. Nuclear chromatin usually was coarsely granular but occasionally of the "india ink" type. No nucleoli were identified. (Fig. 5)

Keratinizing cancer cells: These cells were usually larger and more irregular than parabasal cells. The cytoplasm was eosinophilic or orangeophilic and angulate in shape. The nucleus was usually irregular and markedly hyperchromatic. These cells usually occurred singly. (Fig. 6)

Fiber cells: These cells were long and spindly. The nucleus was markedly hyperchromatic and coarsely granular. The cytoplasm was either cyanophilic or eosinophilic and the nucleus was approximately central to the long axis of the cell. Nucleoli were not seen. (Fig. 7)

Undifferentiated cancer cells: These cells characteristically exhibited considerable variation in size and shape. The nucleus showed a hyperchromatic and either coarsely or finely granular chromatin pattern. The cytoplasm was not prominent. Nucleoli were present occasionally. (Fig. 8)

Following are the cellular patterns which were seen in squamous carcinoma in situ of the uterine cervix. Seventy per cent of the carcinoma-in-situ cells were either large, small or third type cells. The other types of carcinoma-in-situ cells were found less frequently. (Table 1)

In over 63 per cent of cases, small type cells, large type cells or third type cells predominated. In seven of nine cases small type cells constituted 80-100 per cent of the cell population. In one case small type cells comprised 70 per

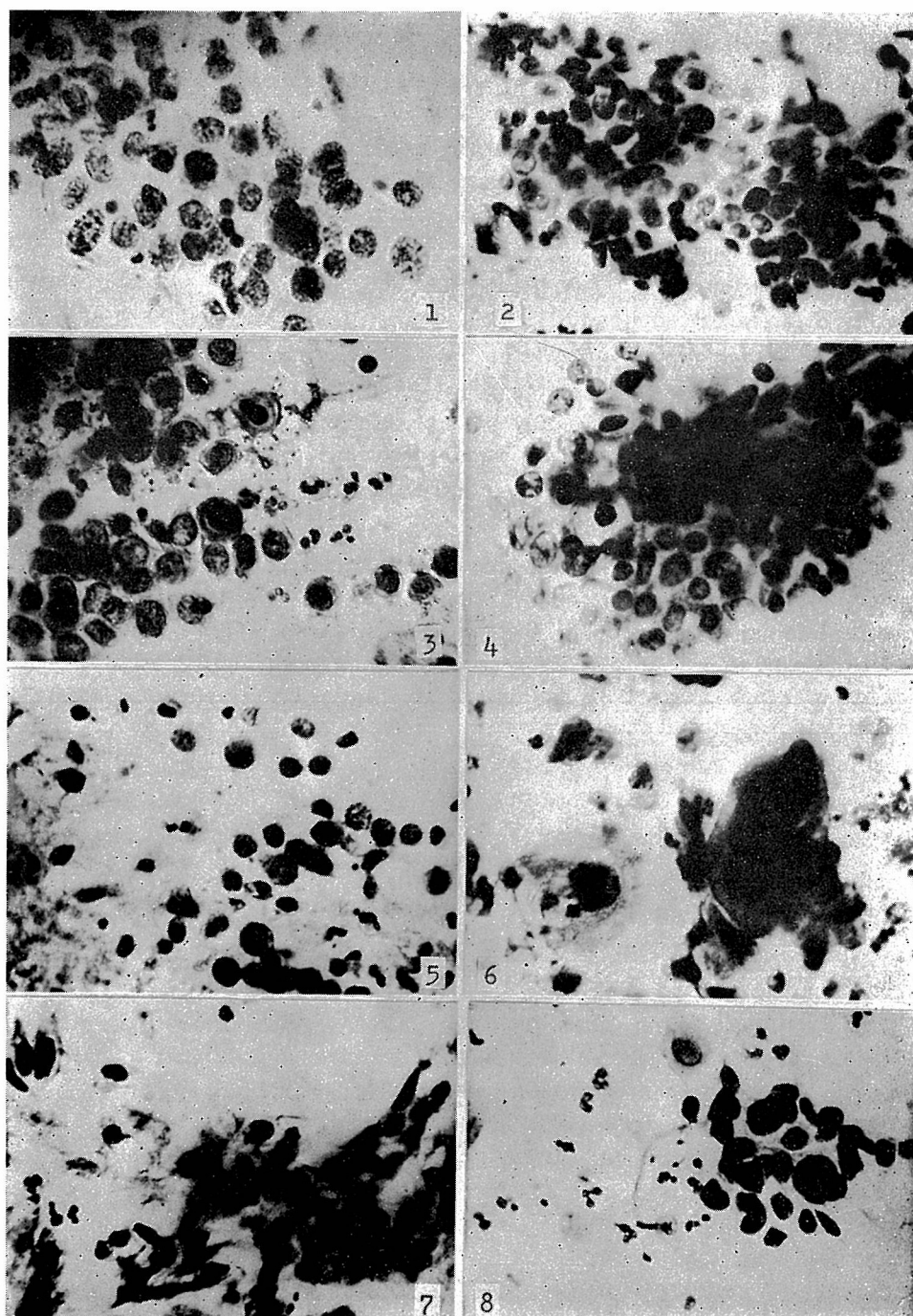


Fig. 1~8: Cytologic Types of Squamous Carcinoma in Situ of the Uterine Cervix.

cent of the cell population and the other 30 per cent were third type cells. In one case small type cells, small cancer cells, keratinizing cancer cells and fiber cells appeared together. In four cases large type cells constituted 80-100 per cent of the cell population, and in one case large type cells comprised 70 per cent of the cell population with 30 per cent third type cells. In three cases third type cells constituted 70-80 per cent of the cell population. The third type cells were accompanied by large type cells, small cancer cells, large non-keratinizing cells and keratinizing cancer cells in limited numbers. The smears of mixed cell types included cases of large and small type cells, large and third type cells, and large and keratinizing cancer cells. In one case fiber cells were the only cellular evidence of carcinoma in situ. In 84.6 per cent of cases in which large, small and third type cells were present, smears contained 50 per cent or more small, large and third type cells. (Table 2)

Table 1. Average percentage distribution of cell types.

Cell type	Percent of total cell population
Small type cells	31.6
Large type cells	23.0
Third type cells	14.6
Large non-keratinizing cells	10.3
Small cancer cells	9.4
Keratinizing cancer cells	6.5
Fiber cells	3.5
Undifferentiated cancer cells	1.1
Total	100.0

Table 2. Predominant malignant cell type per case.

Cell type	Number of cases
Small type cells	9
Large type cells	5
Third type cells	6
Large non-keratinizing cells	3
Small cancer cells	2
Fiber cells	1
Large and small type cells	2
Large and third type cells	1
Large and keratinizing cancer cells	1
Total	30

DISCUSSION

There are no specific cytologic features which can be used consistently in making a diagnosis of squamous carcinoma in situ, in spite of many morphological investigations concerning the cells desquamated from the uterine cervix. Reagan et al. and other investigators, however, have emphasized the diagnostic significance of some nuclear and cytoplasmic changes.⁷⁻⁹⁾¹²⁾¹⁵⁾ Some authors have predicted, correctly, the subsequent tissue diagnosis from cytologic specimens in 80 per cent or more their cases.¹⁾⁴⁾ It is possible that the incorrect diagnosis may have been due to the variability of the morphological patterns of cells which exfoliate from the lesions.¹⁻³⁾⁵⁾⁷⁾⁸⁾¹⁰⁾¹⁴⁾

Siegler has divided histologic sections of squamous carcinoma in situ into four types: basal cell type, keratinizing cell type, pleomorphic cell type and small cell type.¹⁰⁾ He also recognizes four specific cell types which desquamate from these lesions and which are characterized by corresponding terminology.¹⁰⁾ Reagan et al. describe six histologic types of squamous carcinoma in situ and these correspond to six cell types which exfoliate from the lesions.⁸⁾ In this investigation the small type cells, large type cells, small cancer cells and large non-keratinizing cells seen in the smears were also identified in the corresponding histologic sections. The keratinizing cancer cells, fiber cells and undifferentiated cancer cells in the histologic sections appeared on the surface of the abnormal epithelium and were thought to represent degenerated forms.

Gard et al. subdivided cell types from squamous carcinoma in situ according to a modification of Siegler's patterns: keratinizing cancer cells, third type cells, clustered cancer cells, small malignant cells, fiber cells, large non-keratinizing cells and undifferentiated cancer cells. It has been suggested that clustered cancer cells strongly resemble clustered third type cells, showing non-isodiametric pattern.²⁾ In this investigation it was recognized that both clustered cancer cells and third type cells included two kinds of cells composed of large type and small type cells. For this reason, the broad third type cell group was subdivided into three types: large type cells, small type cells and third type cells according to the criteria mentioned above.

Gard et al. have described that in 38 per cent of their carcinoma in situ patients over 50 years of age approximately 50 per cent of the malignant cells were third type cells. Ninety-four per cent of the patients under 50 years of age revealed 50 per cent or more third type cells.²⁾ Graham noted that in slightly over 77 per cent of her squamous carcinoma in situ cases, smears contained 50 per cent or more third type cells.¹⁾ In this investigation approximately 70 per cent of the cancer cells were third type group cells, including large, small and third type cells.

In slightly over 84 per cent of the carcinoma in situ cases, smears contained 50 per cent or more third type group cells. The third type cells sometimes contained "grooving" nuclei with relatively prominent cellular borders. An associated dysplasia with squamous carcinoma in situ has been noted in approximately 80 per cent of cases.⁶⁾ In this study dysplastic cells were present in nearly 77 per cent of the cases. The cells with "grooved" nuclei may originate from epithelium of severe dysplasia associated with squamous carcinoma in situ.

Gard et al. have reported that keratinizing cancer cells predominated in 9 of 21 cases of patients over 50 years of age, and suggested that such cells originate from third type cells and represent a senescent form.³⁾ None of the cases in this investigation revealed a predominance of keratinizing cancer cells. This may be due to the small number of cases of patients over 50 years of age used in this study.

Tweeddale et al. reported that the predominant neoplastic cell type of patients with microinvasive squamous carcinoma of cervix was a large non-keratinizing cell with prominent nucleoli.¹³⁾ The presence of prominent nucleoli in such cells is suggestive of a possible microinvasion as nucleoli did not usually appear in lesions which were "in-situ".

Reagan and other investigators have reported that over 80 per cent of smears from their cases had moderate or many cancer cells.⁴⁾⁷⁾¹⁵⁾ It is obvious that the number of cells in the specimen is strongly influenced by the technique of sample collection and the interval of sampling. It has been reported that the initial sampling in squamous carcinoma in situ usually shows an abundance of cells.⁸⁾

Degenerated erythrocytes were more characteristic of cell specimens taken from patients with invasive squamous carcinoma.⁹⁾¹⁵⁾ The presence of erythrocytes in cases of squamous carcinoma in situ may be related to the presence of capillaries in superficial areas of the neoplastic epithelia. Song et al. have reported the finding of capillaries in tissue sections was found in 17 out of 98 specimens of squamous carcinoma in situ.¹¹⁾ An inflammatory exudate was reported to be associated with 68 per cent of the cases studied by Reagan et al. Bacteria flora, presence of trichomonads and inflammatory cells was similar in microinvasive squamous carcinoma and carcinoma in situ according to Tweeddale et al.¹³⁾ In this study approximately 77 per cent of the cases had moderate or severe inflammatory response.

Since most of the cases in this study displayed several neoplastic cell types, it is suggested that knowledge as to the cytologic variations which may occur in cases of squamous carcinoma in situ is important in making a correct cytologic diagnosis.

SUMMARY

The neoplastic cells from 30 cases of squamous carcinoma in situ of the uterine

cervix have been cytologically subdivided into the following types: small type cells, large type cells, third type cells, large non-keratinizing cells, small cancer cells, keratinizing cancer cells, fiber cells and undifferentiated cancer cells. Small type cells, large type cells and third type cells were commonly seen in the cytologic preparations and one of these types comprised the predominant cancer cell in every case. The cases of mixed type with large and small type cells, large and third type cells, and large and keratinizing cancer cells were not common.

Knowledge of the significance of such cell types may be helpful in making a correct cytologic diagnosis. Furthermore, investigations along these lines provide future clues as to growth characteristics of squamous carcinoma in situ of the uterine cervix.

REFERENCES

- 1) Graham, R. M. : Symposium on carcinoma in situ. *Acta Cytol.*, **5**: 425-436, 1961.
- 2) Gard, P. D., Fields, M. J., Nobli, E. J. and Tweeddale, D. N. : Comparative cytopathology of squamous carcinoma in situ of the cervix in the aged. *Acta Cytol.*, **13**: 27-35, 1969.
- 3) Koss, L. G. : *Diagnostic cytology and its histopathologic bases*, 2nd ed. Philadelphia, J.B. Lipincott Co., 1968, pp. 127.
- 4) Okagaki, T., Lerch, V., Younge, P. A., McKay, D. G. and Kevorkian, A. Y. : Diagnosis of anaplasia and carcinoma in situ by differential counts. *Acta Cytol.*, **6**: 343-347, 1962.
- 5) Old, J. W., Wielenga, G. and Haam, E. V. : Squamous carcinoma in Situ of the uterine cervix. I. Classification and histogenesis. *Cancer*, **18**: 1598-1611, 1965.
- 6) Patten, S. F. : *Diagnostic cytology of the uterine cervix*, Baltimore, Williams & Wilkins Co., 1969.
- 7) Reagan, J. W., Seidemann, I. L. and Saracusa, Y. : The cellular morphology of carcinoma in situ and dysplasia or atypical hyperplasia of the uterine cervix. *Cancer*, **6**: 224-235, 1953.
- 8) Reagan, J. W. and Hamonic, M. J. : The cellular pathology in carcinoma in situ. A cytohistopathological correlation. *Cancer*, **9**: 385-402, 1956.
- 9) Roberts, T. W. and Linkins, T. : Differentiation between intramucosal and invasive carcinoma of the cervix by cytologic smear. Is it reliable? *Acta Cytol.*, **8**: 280-283, 1964.
- 10) Siegler, E. E. : Symposium on carcinoma in situ. *Acta Cytol.*, **5**: 428-436, 1961.
- 11) Song, J., Nettles, J. B. and Sams, J. L. : Circulating tumor cells in patients with carcinoma in Situ of the cervix uteri. *Amer. J. Obstet. Gynec.*, **104**: 713-726, 1969.
- 12) Spjut, H. J. and Fechner, R. E. : Cytologic diagnosis of cervical dysplasia and carcinoma in situ. *Clin. Obstet. Gynec.*, **10**: 785-807, 1967.
- 13) Tweeddale, D. N., Langembach, S. R., Roddick, J. W. and Holt, M. L. : The cytopathology of microinvasive squamous cancer of the cervix uteri. *Acta Cytol.*, **13**: 447-454, 1969.
- 14) Tweeddale, D. N. and Roddick, J. W. : Histologic types of squamous carcinoma in situ of the cervix. *Obstet. Gynec.*, **33**: 35-40, 1969.
- 15) Wied, G. L., Legorreta, G. and Rauzy, A. : Cytology of invasive cervical carcinoma and carcinoma in situ. *Ann. N. Y. Acad. Sci.*, **97**: 759-766, 1962.