

Bull Yamaguchi Med Sch 49(3-4):107-113, 2002

A Case of Maxillary Sinus Plasmacytoma and Analysis of Cellular Biological Features

Masamichi Ita¹, Masaki Okafuji¹, Yasuyuki Noutomi¹, Yukoh Saito¹,
Kohsuke Sasaki²

¹The Department of Oral and Maxillofacial Surgery, and. Specific Organ Medicine, Yamaguchi University School of Medicine; 1-1-1 Minamikogushi Ube, 755-8505, Japan

²The Department of Pathology, and. Molecular Science & Applied Medicine, Yamaguchi University School of Medicine; 1-1-1 Minamikogushi Ube, 755-8505, Japan

(Received January 24, 2002, revised December 2, 2002)

Key words: Plasmacytoma, Maxillary sinus, DNA content
comparative genomic hybridization

Abstract Extramedullary plasmacytoma is a rare malignant tumor that generally arises in the head and neck region. We encountered a plasmacytoma located in the maxilla, maxillary sinus, and ethmoidal sinuses. The tumor was composed of premature cells showing positive staining for λ light chain immunoglobulin. Several types of examination, including M protein analysis, ruled out multiple myeloma. After a debulking operation, a total of 50 Gy of radiation failed to shrink the tumor. To prevent the tumor from progressing to multiple myeloma, the patient underwent chemotherapy. After this treatment, the tumor showed no growth. Flow cytometry and comparative genomic hybridization studies showed the tumor DNA to be diploid, containing few chromosomal aberrations. On the basis of these findings, it was thought that the tumor malignancy of plasmacytoma might be relevant to DNA ploidy pattern and chromosomal aberration.

Introduction

Plasmacytoma is a malignant tumor that originates from plasma cells. In general, multiple myeloma, one type of plasmacytomas, is considered to occur in bone such as rib, sternum, and cranial bones. Some types of plasmacytomas such as simple myeloma, solitary plasmacytoma, or extramedullary plasmacytoma are considered to occur as a solitary tumor in soft tissue or an endocrine organ. Plasmacytomas frequently arise in the nasopharynx, nasal cavity, or maxillary sinus of the head and neck region.¹⁾ The standard treatment of plasmacytoma involves radiation,

chemotherapy, and surgery if possible. We treated a patient with a huge plasmacytoma located in the maxillary sinus by debulking operation, radiation, and chemotherapy. Radiotherapy was not effective, but the tumor size did not increase after additional chemotherapy. We herein describe the case and the flow cytometry and comparative genomic hybridization (CGH) characteristics of the tumor.

Case report

A 61-year-old man sought evaluation at our hospital because of swelling of the right-sided cheek region, which he had noted for 1 month. At his first visit, the skin over the cheek, the right pal-

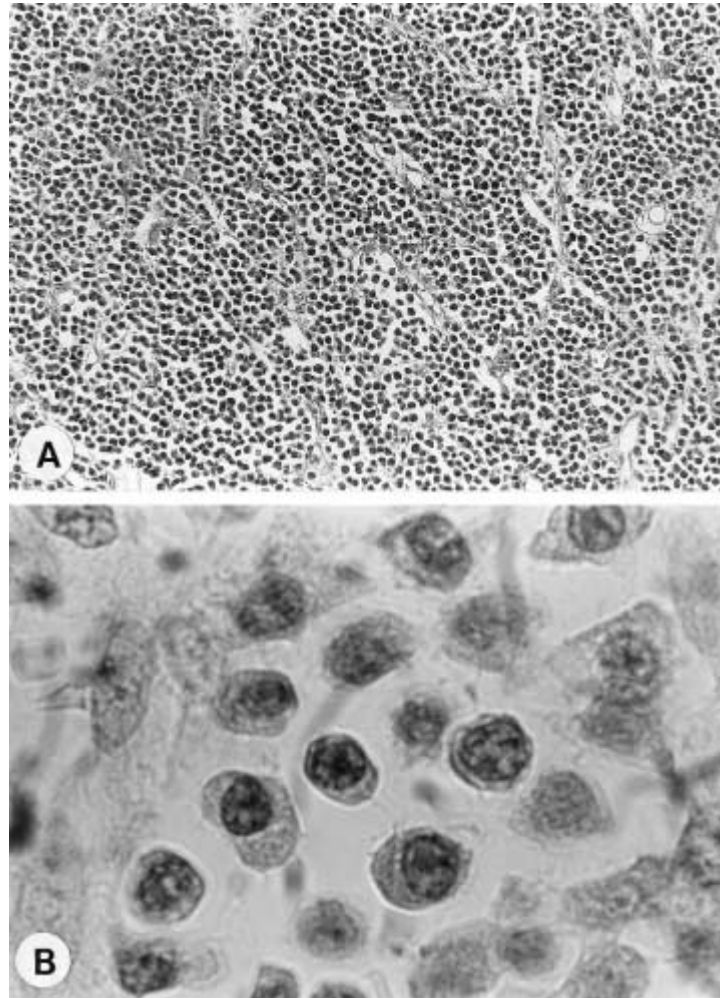


Fig. 1 Histological features. A) Plasmacytoid cells diffusely infiltrated. B) Tumor cells revealed eccentric nuclei and perinuclear halos. (hematoxylin-eosin stain, A: original magnification x100; B: original magnification x1000).

ate was swollen, and the patient complained of slight pain in these sites. A biopsy specimen was taken from the maxillary region. The mass consisted of immature small cells similar to plasma cells. These cells had round, eccentric nuclei with dense chromatin clumps arranged along the nuclear membrane in cartwheel fashion and paranuclear hofs in the cytoplasm (Fig. 1). Immunostaining of T-cell markers (MT-1, UCHL-1) and B-cell markers (MB-1, L-26) produced negative results. Moreover, λ light chain immunoglobulin staining produced positive results. The tumor was diagnosed as plasmacytoma.

Many examinations were done to determine whether the patient had multiple myeloma or solitary plasmacytoma. Computed tomography and magnetic resonance

imaging showed that the mass to be located in the maxillary sinus and ethmoidal sinuses (Fig. 2). ^{67}Ga scintigraphy showed tracer accumulation in these regions. However, $^{99\text{m}}\text{Te}$ -hydroxymethylene diphosphonate accumulated in the clavicle, scapula, rib, and lumbar vertebrae as well as in the maxilla. Lymphocyte count and differential lymphocyte count were in the normal range, and plasmacytes were not found in peripheral blood. The results of bone marrow puncture showed that plasmacytes had increased to 3% of cells or as much as three times the normal level. Although protein electrophoresis showed a slight increase in γ fraction with increasing Ig G, immunoelectrophoresis did not show M protein in urine, which is a diagnostic indicator of multiple myeloma.

Therefore the tumor was diagnosed as a solitary extramedullary plasmacytoma originating in the maxillary sinus.

To further investigate tumor characteristics, we used flow cytometry to measure DNA content and to determine the DNA index, or ratio of G₀/G₁ peak channels of the tumor cells to those of normal lymphocytes. We also used comparative genomic hybridization to detect aberrations in the DNA copy number.²⁾ Before doing these examinations, we explained their purpose to the patient and obtained his consent. The procedures followed conventional methods. Flow cytometry showed DNA diploidy (Fig. 3); moreover, results of CGH did not indicate aberration in the DNA copy number (Fig. 4). On the basis of these findings, we considered this tumor a low-grade malignancy because DNA aneuploidy and aberrations in the

DNA copy number generally reflect enhanced tumor malignancy.

The treatment of plasmacytoma may include surgery, radiation therapy, and chemotherapy. In this case, we planned radical surgery to be followed by radiation therapy. However, we could not get the patient to agree to orbital exenteration so initial treatment consisted of a debulking operation followed by a total of 50 Gy of fractionated radiotherapy in the duration of 48 days. After operation, the tumor remained in the ethmoidal sinuses. Radiotherapy was not effective, since it resulted in only 30% of decrease in the tumor bulk. As a final measure, chemotherapy consisting of vincristine (0.4 mg/body/day), adriamycin (10 mg/body/day), and dexamethasone (40 mg/body/day) was used for 4 days to prevent the tumor from converting to multiple

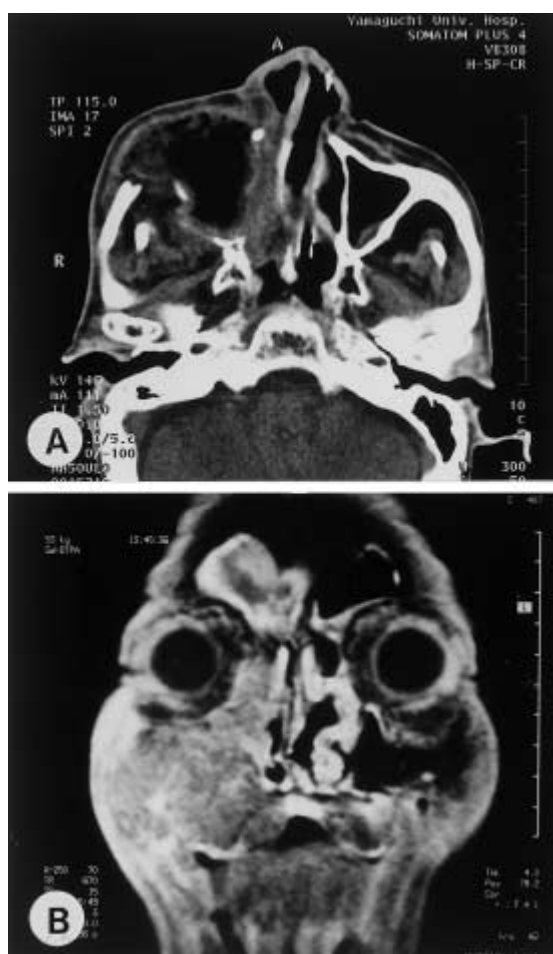


Fig. 2 Magnetic resonance image revealed bony destruction and ethmoidal sinuses involvement by tumor.

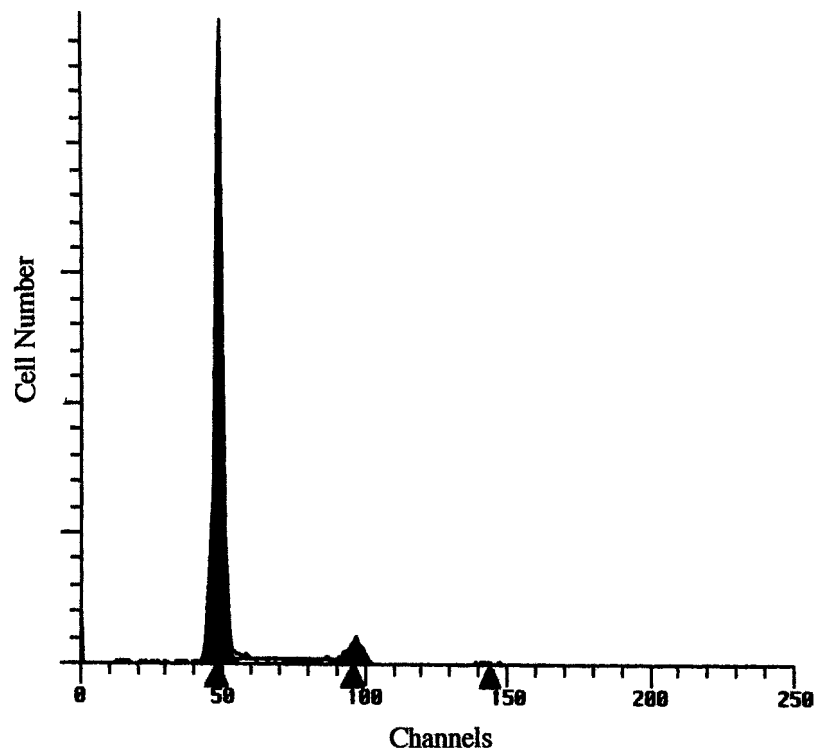


Fig. 3 DNA histogram showing a diploid pattern.

myeloma. Thirty months after discharge, neither tumor enlargement as shown by computed tomography and magnetic resonance imaging nor conversion to multiple myeloma was noted.

Discussion

Susnerwala et al.³⁾ has reported that the rate of conversion from solitary plasmacytoma to multiple myeloma ranges from 10% to 30%. Because the prognosis of patients with multiple myeloma is poor compared to that of patients with solitary plasmacytoma⁴⁾, preventing conversion to multiple myeloma is important. Combination therapy with surgery and radiation for solitary plasmacytoma is usually selected because of its radiosensitivity. Solitary plasmacytoma has been reported to be radiosensitive and effective radiation doses range from 30 to 80 Gy. In this case, 50 Gy of radiotherapy resulted in 30% tumor reduction, i.e., no change. Chemotherapy is occasionally used to prevent conversion.⁵⁾ Since the tumor growth in our case has not been seen 2 years af-

ter chemotherapy, the post-radiation chemotherapy may control tumor growth or conversion. Previous report has shown the efficacy of chemotherapy with alkylating agents in patients with a locally invasive tumor.^{1,6,7)} Considering the ineffectiveness of radiotherapy in our case, chemotherapy will be used when this tumor begins to proliferate again.

To investigate the characteristics of this tumor, we used flow cytometry and CGH. Flow cytometry showed that this tumor was DNA diploid and had a normal DNA content. In general, DNA content is thought to be related to tumor malignancy. San Miguel et al.⁸⁾ note that 50% to 70% of multiple myeloma patients have aneuploid tumors, and the prognosis of patients with DNA diploid tumors is better than that of those with DNA aneuploid tumors.⁹⁾ These reports suggest that the malignancy of a DNA diploid tumor is lower grade, and its growth potential is relatively low. To the best of our knowledge, there is no report describing the relation between therapeutic effects and

DNA ploidy patterns in solitary plasmacytoma. Therefore, it is unknown whether DNA diploid tumors are sensitive to chemotherapy or radiotherapy, despite the good prognosis of patients with DNA diploid tumors as described above.

CGH analysis also indicated that the malignancy of the tumor in this case was low grade. Reports of such analysis of chromosomal changes in multiple myeloma or plasmacytoma or both have indicated several chromosomal aberrations. Cigudosa et al.⁴⁾ described gain of chromosome 19 and deletion of chromosome 13 and 19 in multiple myeloma. Aalto et al.¹⁰⁾ emphasized loss of chromosome 13q in plasmacytoma. Avet-Loiseau et al.¹¹⁾ reported gains of chromosome 1q and 7 and losses of chromosome 13q and 14q in multiple myeloma and plasma cell leukemia. These descriptions indicated that chromosome 13 may play an important role in carcinogenesis, tumor progression, and malignancy. However, our case did not show any chromosomal aberration, in spite of the large size of the tumor. DNA diploid tumors

generally have few chromosomal aberrations in comparison to aneuploid tumors. De Angelis et al.¹²⁾ explain this finding by stating that diploid tumors result from mutations other than the acquisition of gross chromosomal aberrations. Actually tumor malignancy seems to be related to DNA ploidy pattern or chromosomal aberrations. The characteristic of the tumor in this case is that chromosomal aberration was not detected by CGH despite its hyperploidy, and the tumor did not remarkably decrease in size after radiotherapy and chemotherapy. Especially radiotherapy is the most useful therapeutic modality for local control. In fact, Tsang et al. described excellent therapeutic effects of radiotherapy that all of 40 cases of solitary plasmacytoma responded to radiotherapy.⁷⁾ It is interesting to note that the tumor did not show much response to radiotherapy in this case. As described earlier, some researchers suggested that chromosomal aberration such as loss of chromosome 13 is of importance on tumor malignancy in plas-

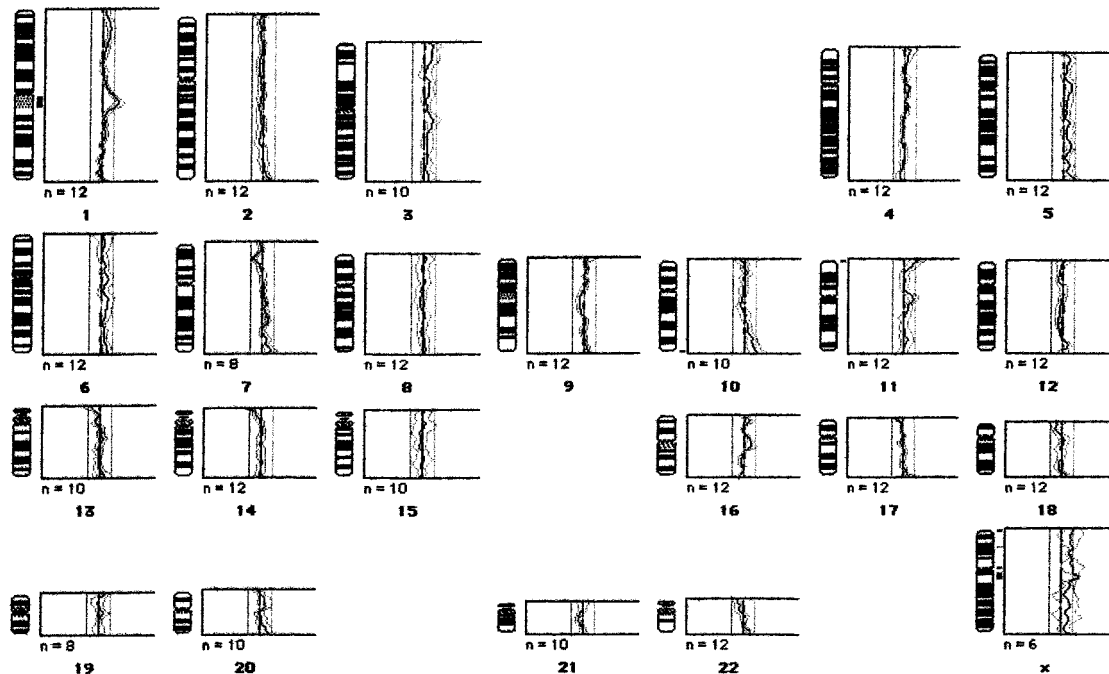


Fig. 4 Ratio profile of comparative genomic hybridization analysis. Aberration of the DNA copy number was not detected. The tumor cell and normal were labeled with green and red fluorescence, respectively. The mid-line represents a fluorescence ratio of 1.0; the line on either side of midline represent ratio of 0.8 and 1.2. The thick line represents a fluorescence intensity ratio of the specimen, and located between 0.8 and 1.2.

Table1 Results of laboratory tests

White Blood Cell Count	7600/mm ³
N.Band	1 %
N.Segment	44%
Eosinophhil	3 %
Basophil	1 %
Lymphocyte	43%
Monocyte	8 %
Plasma cell in bone marrow	3 %
γ Fraction	positive
M protein	negative
Ig G	1790mg/dL
Ig A	283mg/dL
Ig M	82.9mg/dL
Bence Jones Protein	negative

macytoma.^{10,11)} Although we could not clarify the correlations among chromosomal aberration, DNA ploidy pattern, radiosensitivity, and chemosensitivity, our case has brought forward the questions of whether chromosomal aberration in solitary plasmacytoma is related to clinical outcome, patient prognosis, or conversion to multiple myeloma.

At present the patient is monitored of conversion at regular intervals including change of ^{99m}Te-hydroxymethylene diphosphate accumulations in the clavicle, scapula, rib, and lumbar vertebrae by the hematologist. So far, this tumor has not shown increasing in size after the treatment. Although there is no obvious reason why the tumor remains stable, it was supposed that malignancy including proliferative activity of the tumor cells is relatively low or the anticancer drugs used after radiation have suppressed tumor growth for longer periods. Since the patient still had residual plasmacytoma in the sigmoid region, we must continue to pay a careful attention to note possible progression of the residual tumor to multiple myeloma.

Acknowledgement

This study was supported by a Grant-Aid(13672100) for Scientific Research (C)from the Ministry of Education, Culture Sport, Science and Technology of Japan.

Reference

- 1) Liebross RH, Ha CS, Cox JD, Weber D, Delasalle K, Alexander R: Clinical course of solitary extramedullary plasmacytoma. *Radiother Oncol*, 52:245-249,1999.
- 2) Okafuji M, Ita M, Oga A, Hayatsu Y, Matsuo A, Shinozaki F, Sasaki K: The relationship of genetic aberrations detected by comparative genomic hybridization to DNA ploidy and tumor size in human oral squamous cell carcinomas. *J Oral Pathol Med*, 29:226-231, 2000.
- 3) Susnerwala SS, Shanks JH, Banerjee SS, Scarffe JH, Farrington WT, Slevin NJ: Extramedullary plasmacytoma of the head and neck region: clinicopathological correlation in 25 cases. *British J Cancer*, 75:921-927, 1997.
- 4) Cigudosa JC, Rao PH, Calasanz MJ, Odero MD, Michaeli J, Jhanwar SC, Chaganti RS: Characterization of non-random chromosomal gains and losses in multiple myeloma by comparative genomic hybridization. *Blood*,15:3007-3010, 1998.
- 5) Holland J, Trenkner DA, Wasserman TH, Fineberg B: Plasmacytoma treatment results and conversion to myeloma. *Cancer*, 69:1513-1517, 1992.
- 6) Soesan M, Paccagnella A, Chiarion-Sileni V, Salvagno L, Firnasiero A, Sotti G, Zorat AL, Faveret-

- to A, Fiorentino M: Extramedullary plasmacytoma: clinical behavior and response to treatment. *Ann Oncol* , **3**: 51-57, 1992.
- 7) Tsang RW, Gospodarowicz MK, Pintilie M, Bezjak A, Wells W, Hodgson DC, Stewart AK: Solitary plasmacytoma treated with radiotherapy: impact of tumor size on outcome. *Int J Radiat Oncol Boil Phys*, **50**:113-120, 2001.
- 8) San Miguel JF, Garcia-Sanz R, Gonzalez M, Orfao A: DNA cell content in multiple myeloma. *Leuk Lymphoma*, **23**:33-41, 1996.
- 9) San Miguel JF, Garcia-Sanz R, Gonzalez M, Orfao A: Immunophenotype and DNA cell content in multiple myeloma. *Baillieres Clin Haematol*, **8**: 735-759, 1995.
- 10) Aalto Y, Nordling S, Kivioja AH, Karaharju E, Elomaa I, Knuutila S: Among numerous DNA copy changes, losses of chromosome 13 are highly recurrent in plasmacytoma. *Genes Chromosomes Cancer*, **25**:104-107, 1999.
- 11) Avet-Loiseau H, Andree-Ashley LE, Moore D 2nd, Mellerin MP, Feusner J, Bataille R, Pallavicini MG: Molecular cytogenetic abnormalities in multiple myeloma and plasma cell leukemia measured using comparative genomic hybridization. *Genes Chromosomes Cancer*, **19**:124-133, 1997.
- 12) De Angellis PM, Clausen OPF, Schjoldberg A, Stokke T: Chromosomal gains and losses in primary colorectal carcinomas detected by CGH and their associations with tumour DNA ploidy, genotypes and phenotypes. *British J Cancer*, **80**:526-535, 1999.