

Bull Yamaguchi Med Sch 49(3-4):49-53, 2002

Abdominal Aortic Aneurysm Surgery in High-Risk Patient: Retrograde Anastomosis Using a Ringed Y-graft

Satoru Kurata

Department of Surgery, Yamaguchi Central Hospital,
77-Osaki, Hofu, Yamaguchi, 747-8511, Japan

(Received November 21, 2002, revised December 2, 2002)

Key words: Abdominal aortic aneurysm, High-risk patient, Ring graft
Retrograde anastomosis, Aortic cross-clamp time

Abstract In September 1986, I developed a ringed Y-graft (RYG). First, non-suture technique with RYG was applied to 20 high-risk patients with abdominal aortic aneurysm. The RYG method was evaluated with the conventional Y-graft (CYG) method (21 cases). Aortic cross-clamp time was 37 ± 3.4 minutes in the RYG group and 56 ± 3.1 minutes in the CYG group. The RYG method reduced aortic cross-clamp time significantly ($P < 0.001$). All the patients with both groups recovered and were discharged from the hospital. Next, retrograde anastomosis technique with RYG was applied to 9 high-risk patients with cardiac or renal complications, (eight men and one woman) with a mean age of 74 years (range: 65-82 years). The aortic cross-clamp time ranged from 6-18 minutes with an average of 9:09 minutes. None of the patients developed postoperative complications and all of them have remained well after discharge.

I succeeded in reducing the aortic cross-clamp time from 56 to 9 minutes by retrograde anastomosis technique, in which anastomosis is started at the peripheral end of the graft. The retrograde anastomosis technique using RYG is useful for high-risk abdominal aortic aneurysm repair.

Introduction

Surgical treatment for abdominal aortic aneurysm (AAA) is well established and generally safe. However, in various high-risk patients, the conventional method of aneurysmectomy, combined with replacement by a prosthetic graft, is not always safe. In September 1986, I developed a ringed Y-graft (RYG) and achieved good results in treating high-risk AAA patients using this graft.¹⁾ In patients with complications, such as heart or renal disease,

and in patients who require clamping of the renal arteries, it is considered desirable to keep the aortic cross-clamp time as short as possible. I succeeded in reducing the aortic cross-clamp time from 56 to 37 minutes by non-suture technique using this RYG and from 37 to 9 minutes by retrograde anastomosis technique²⁾, in which anastomosis is started at the peripheral end of the graft.³⁾

Patients and Methods

The RYG was constructed using a Bard® intraluminal graft (20-22 mm in diame-

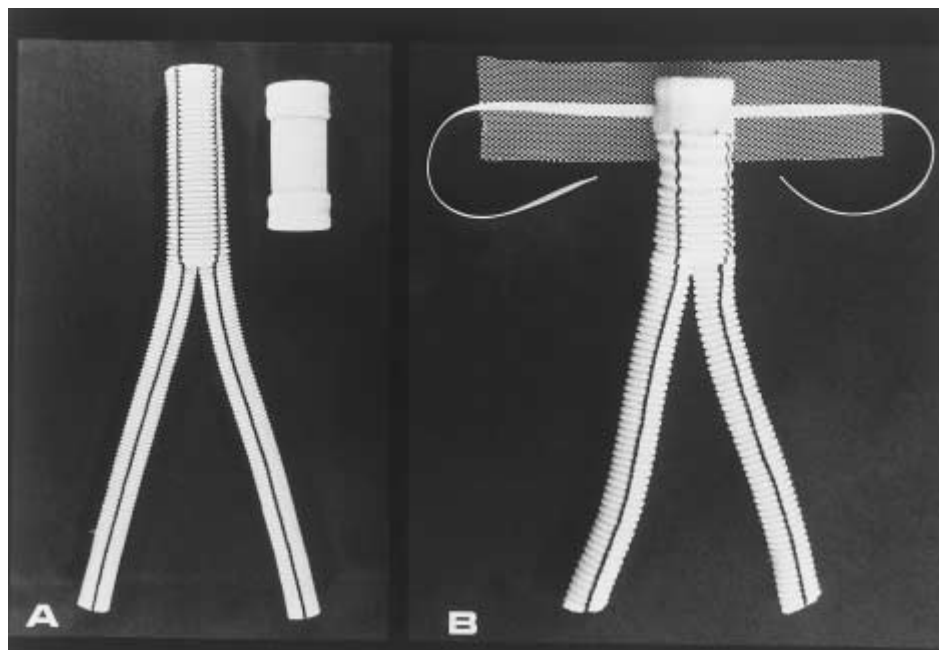


Fig. 1 (A) : Intraluminal graft made by Bard-USCI and Cooley's Ygraft made by Meadox Medical
 (B) : Ringed Y-graft with Dacron mesh and tape

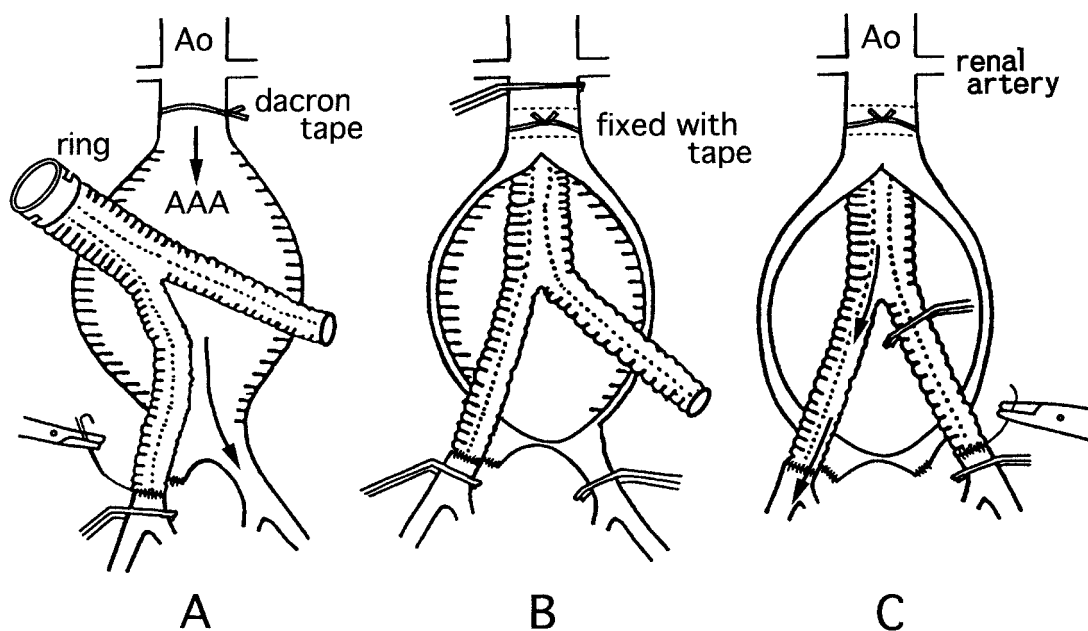


Fig. 2 Retrograde anastomosis using ringed Y-graft

A : Right limb of the graft is sutured.

B : Aorta is cross-clamped and proximal anastomosis completed.

C : Left anastomosis is accomplished with right limb open.

ter), and a DeBakey Vascular II® (16-18 mm in diameter), or a Cooley® Y-graft (16 mm in diameter) (Figure 1) was used for the trial. The sites of anastomosis of the graft with the abdominal aorta and with the common iliac arteries or external iliac

arteries, as well as the length of the graft, were determined before the operation. In preparation, Dacron tape and mesh were threaded around the abdominal aorta at the expected site of anastomosis with the graft. The lumbar arteries were ligated

from outside the aneurysm wall. The operative procedure of retrograde anastomosis technique using a RYG is as follows: The right common, external, and internal iliac arteries were clamped, and the right limb of the RYG was anastomosed with the common or external iliac artery (Figure 2-A). Next, abdominal aorta and the left common iliac artery were clamped, and a longitudinal incision was made in the aneurysm. After removal of thrombus from the aneurysm and adequate lavage using saline, the ringed section at the proximal end of the graft was inserted into the abdominal aorta and ligated using the Dacron tape and mesh that had been passed around the aorta in advance (non-suture technique) (Figure 2-B). Air and debris were removed from the left limb of the graft, and blood flow was restarted. Finally, the left limb of the graft was anastomosed to the common iliac artery or external iliac artery (Figure 2-C).

First, I began the present study to practice nonsuture technique with RYG to 20 high-risk patients. This RYG method, ex-

cept for the ruptured case, was compared with the conventional Y-graft (CYG) method (21 cases) in terms of age, size of aneurysm, operating time, blood loss, and aortic cross-clamp time. The results were statistically analyzed by use of Student's t test.

Next, I applied retrograde anastomosis technique using a RYG to 9 patients. The subjects were eight men and one woman, with ages ranging from 65 to 82 years (average 74 years). Concomitant diseases included angina pectoris plus chronic renal failure in three patients, angina pectoris alone in two patients, thoracoabdominal aortic aneurysm plus chronic renal failure in one patient, chronic renal failure in one patient, aortic stenosis in one patient and aortic regurgitation in one patient (Table 1). One of the patients with angina pectoris and chronic renal failure underwent hemodialysis twice preoperatively.

Results

In the first study (non-suture technique), the mean age was 75 ± 1.7 years in the

Table 1 Number of cases with concomitant diseases

Concomitant diseases	Number of cases
Angina pectoris + CRF	3
Angina pectoris	2
Thoracoabdominal aortic aneurysm + CRF	1
CRF	1
Aortic stenosis	1
Aortic regurgitation	1
CRF : Chronic Renal Failure	

Table 2 Comparison between RYG group and CYG group

	RYG group	CYG group
Age (year)	75 ± 1.7	$69 \pm 1.5^*$
Size of aneurysm (cm)	5.7 ± 0.3	5.4 ± 0.3
Operating time (hr)	3.8 ± 0.2	4.4 ± 0.2
Blood loss (ml)	755 ± 88	$1204 \pm 170^*$
Aortic clamp time (min.)	37 ± 3.4	$56 \pm 3.1^{**}$

* $P < 0.05$, ** $P < 0.001$, Mean \pm SE

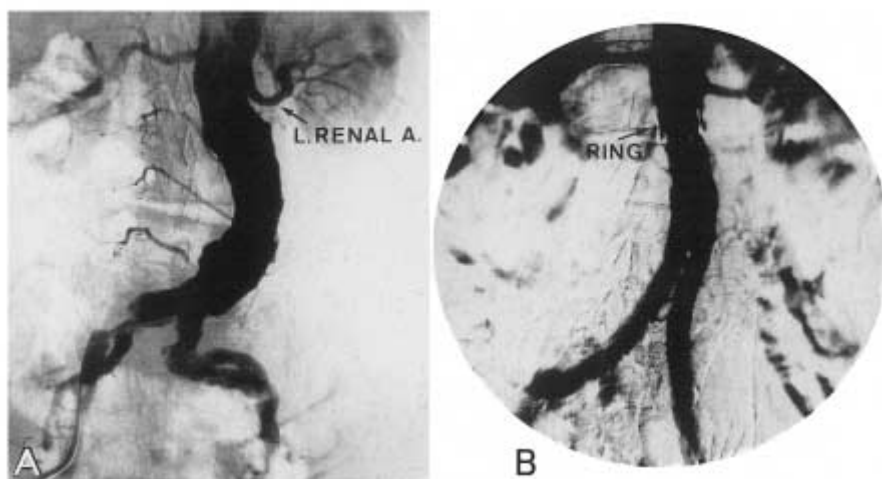


Fig. 3 A : Preoperative aortogram shows AAA beginning directly under renal arteries
 B : Postoperative aortogram. Ring-attached part is just under the branch of the left renal artery (marked with an arrow) .

RYG group and 69 ± 1.5 years in the CYG group showing a significant difference between the two groups ($p < 0.05$) . Sizes and operating time in the RYG group were identical to those in the CYG group. Blood loss was significantly less in the RYG group (755 ± 88 ml) than in CYG group (1204 ± 170 ml) ($p < 0.05$) . Mean aortic cross time was 37 ± 3.4 minutes in the RYG group and 56 ± 3.1 minutes in the CYG group. The RYG method reduced the clamping time significantly ($p < 0.001$) (Table 2) . All the patients of both groups recovered and were discharged from the hospital.⁴⁾ Postoperative aortograms showed normally functioning grafts without hemodynamic problems (Figure 3) .

In the second study (retrograde anastomosis technique) , the aortic cross-clamp time ranged from 6-18 minutes, with an average of 9:09 minutes The operating time ranged from 3:05-4:35 hours, with an average of 3:34 hours. Blood loss ranged from 200 ml to 2000 ml, with an average of 1156 ml. None of the patients had perioperative cardiac or renal complications. All the patients recovered and were discharged from the hospital.

Discussion

Elective and scheduled repair of AAA carries a good prognosis. However, because of the aging of the population, the chance

of operation for AAA in high-risk patients is continuously increasing. In high-risk patients, CYG method is not necessarily a safe procedure.⁵⁾ We must, therefore, devise some ideal operative and supportive techniques in operation for high-risk AAA. Among operative techniques, thromboexclusion and axillo-bifemoral bypass, use of ring graft, and endovascular methods^{6,7,8)} can be considered, while supportive techniques include temporary and partial extracorporeal circulation. Combined axillo-bifemoral bypass and thromboexclusion create extraanatomical bypass, which is associated with the risk of aneurysm rupture or tearing of the clamping site, therefore, this technique is not commonly used. Endovascular techniques using stent grafts are superior because of their low invasiveness, but stent grafts are not indicated in all cases and are not approved in Japan. Furthermore, the long-term prognosis is unknown. Temporary bypass and partial extracorporeal circulation are useful to maintain a stable circulation during operation, but result in a prolonged operating time. To shorten the aortic cross-clamp time and to make the surgical repair of high-risk AAA safe and simple, I devised a new technique utilizing a RYG, in September 1986, with which I was able to shorten the aortic cross-clamp time in high-risk AAA patients from 56

to 37 minutes. Because of the ring, it is not necessary to suture the anastomosis at the proximal end of the graft; the ringed section is inserted into the aorta and the ring is ligated from outside the aorta using a Dacron tape. The procedure seems to be an excellent technique that can be performed perfectly in the shortest time among the existing anastomosing methods on the proximal side in the operation for AAA. An even shorter aortic cross-clamp time can be achieved when a retrograde anastomosis technique is applied to the RYG : while one limb of the graft is anastomosed to the iliac artery, the aorta is not clamped and blood flow through the aorta into the other leg is maintained. After one distal anastomosis is completed, the aorta is clamped and the proximal anastomosis is performed. Because of the ring, the proximal procedure can be completed within a few minutes. Using this method, it was possible to shorten the aortic cross-clamp time to nine minutes. Finally, after declamping the aorta, the anastomosis of the other iliac artery can be performed. Since September 1986, I have applied Bard® intraluminal graft for 10 cases of thoracic aortic aneurysm, seven cases of thoracoabdominal aortic aneurysm, and 81 cases of AAA, and there have been no instances of complications such as development of a new aneurysm at the anastomosis, dislodgement of the ring, or thrombosis.

References

- 1) Kurata, S., Hongo, H., Misumi, K., Kawano, T., Kuroda, Y., Nakayasu, K., Harada, M., Esato, K.: A New Approach for Abdominal Aortic Aneurysm by a Ringed Y Graft. *Vasc. Surg.* **22**: 303-307, 1988.
- 2) Purdy R.T., Beyer, F.C., McCann, W.D., Smith I.D., Mann R.H.: Reduced aortic cross-clamp time in high-risk patients with abdominal aortic aneurysm. *J. Vasc. Surg.* **3**:820-823, 1986.
- 3) Kurata, S., Hirata, K., Kuroki, T., Nawata, S., Nagashima, H., Kuroda, Y., Nakayasu, K., Hongo, H., Zempo, N., Esato, K.: Abdominal Aortic Aneurysm Surgery in Patients with Cardiac and Renal Complications: Retrograde Anastomosis Using a Ringed Y-graft. *Int. J. Angiol.* **10**: 20-23, 2001
- 4) Kurata, S., Hongo, H., Furutani, A., Kaneda, Y., Sakai, H., Kuroda, Y., Nakayasu, K., Esato, K.: A New Approach for Abdominal Aortic Aneurysm by a Ringed Y Graft. *Vasc. Surg.* **26**: 47-52, 1992.
- 5) Akkersdijk, G.J.M., Graaf, Y., Moll, F.L., Varies, A.C., Kitslaar, P.J.E. H.M., Bockel, J.H., Hak, E. Eikelboom, B.C.: Complications of Standard Elective Abdominal Aortic Aneurysm Repair. *Eur. J. Vasc. Endovasc. Surg.* **15**:505-510, 1998.
- 6) May, J., White, G.H., Yu, W., Waugh, R., Stephan, M.S., Sieunarine, K., Chaufour, X., Harris, J.P.: Endoluminal Repair of Abdominal Aortic Aneurysms: Strengths and Weakness of Various Prostheses Observed in a 4.5-year Experience. **4**:147-451, 1997.
- 7) Abou-Zamzam, B.M., Porter, J.M.: Does Endovascular Grafting Represent a Giant Step Forward?. *Semi. Vasc. Surg.* **12**: 235-241, 1999.
- 8) FRY, P.D., MACHAN, L.S.: Early Experience With The Talent Endovascular Prosthesis For Abdominal Aortic Aneurysm. *J. Tokyo. Med. Univ.* **56**: 269-281, 1998.