

Intraureteral Cut with a Maisonneuve Urethrotome for Stricture of the Ureter Subsequent to a Cutaneous Ureterostomy

Tadao KIRIYAMA and Shigeaki HAYASHIDA

Department of Urology, Yamaguchi

University School of Medicine

(Received January 27, 1977)

Stricture of the ureter is one of the troublesome complications which a cutaneous ureterostomy entails and which sometimes may call for redirection or removal of the already diverted urinary tract to relieve lifesustaining kidney function. Two cutaneous ureterostomized patients with ureteral stricture were satisfactorily treated by cutting the stricture with a Maisonneuve urethrotome. Although internal urethrotomy has been refuted without obvious reasons and remains in only limited use, we are convinced that it is a valuable procedure which should be more widely used¹⁾.

Here, it is considered that "internal ureterotomy" means a new adaptation of internal urethrotomy and suggests advent of a new procedure for treating the stricture of the ureter subsequent to a cutaneous ureterostomy.

TECHNIQUE

Before the procedure is attempted, fistulous pyelo-ureterograms must be taken to determine the location and extent of the stricture, and the caliber and course of the involved ureter.

Technique of "internal ureterotomy" is essentially identical to the technique which is used to perform an internal urethrotomy. A filiform is passed through the stricture to the pelvis. Then, the abdominal wall around the stoma pulled down tightly to straighten the ureter, a grooved director is screwed into the filiform and advanced with scrupulous attention into the pelvis with the groove directed ventrally. A blade is set in the groove and slowly advanced until resistance is encountered. The blade is then advanced with a brisk and determined motion, producing a clean cut in the stricture of the anterior wall of the ureter. After withdrawal of the urethrotome, a Robinson catheter is inserted and left in place.

During ureterotomy, both patients complained only of slight prickling pain, because the operation was completed without any anaesthesia. No other complications, including avulsion or appreciable bleeding, were encountered.

CASE REPORT

Case 1. A 64-year-old carpenter, who on October 23, 1967, at the age of 59, had received a radical cystectomy and a bilateral cutaneous ureterostomy for carcinoma of the bladder at the Yamaguchi Red Cross Hospital, visited the outpatient clinic of this hospital on November 16, 1971. He stated that his right-hand catheter had slipped out while he was sleeping and that his doctor was unable to pass it beyond a stricture of the ureter.

Ever since his discharge from the Red Cross Hospital, he had worn indwelling catheters and had them exchanged every two weeks in his home town. According to his doctor, the catheters were inserted at the

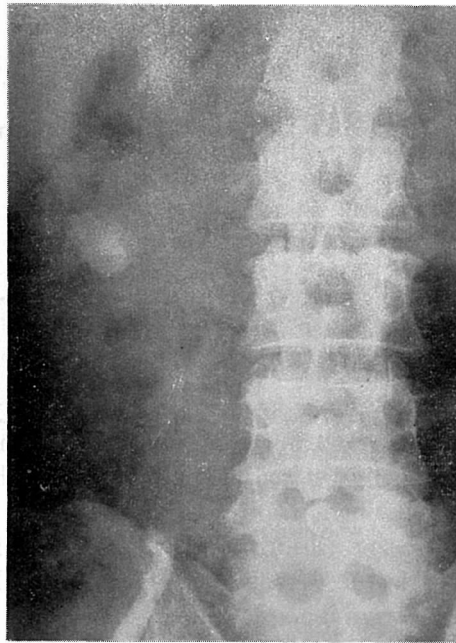


Fig. 1. A fistulous pyelo-ureterogram prior to an internal ureterotomy reveals obstruction of the right ureter just above the ilio-sacral joint. Only a little dye which ascends beyond the obstruction into one of the lower calyces suggests the marked dilatation of the right collecting system.

start with ease, but later on, especially on the right side, insertion became increasingly difficult as the ureteral stricture increased in severity. At last, on October 21, 1969, his right-hand catheter could not be introduced into the pelvis and thus he visited the clinic. He was treated with dilatation to 15F with metal urethral sounds, using the same technique as is used to pass a sound through a urethra. Thereafter, for two years, the patient returned with the same complaint several times a year. Each time he underwent a gradual dilatation and a Robinson catheter was introduced up to the pelvis.

When the patient returned on November 16, 1971, the stricture was so narrow that even a 10F urethral sound could not reach the pelvis. Fistulous pyeloureterograms (Fig. 1) revealed the stricture to be located approximately 10 cm proximal to the ureteral stoma. A filiform was passed through the stricture to the pelvis, and an internal ureterotomy was performed.

Four weeks later, follow-up ascending pyelo-ureterograms (Fig. 2)

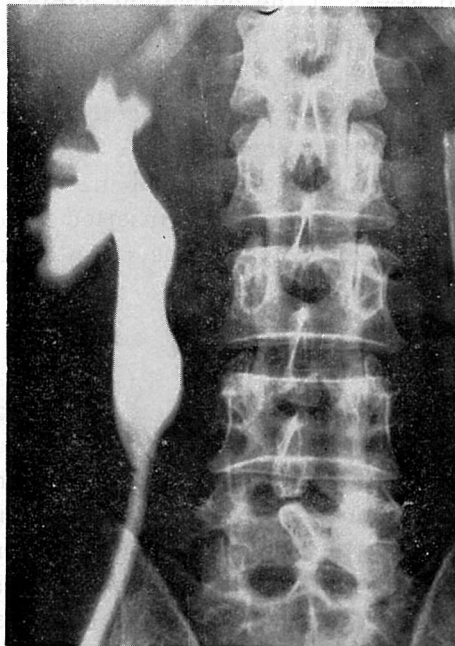


Fig. 2. An ascending pyelo-ureterogram 4 weeks following the ureterotomy demonstrates that the entire ureter extending from the pelvi-ureteral junction to the stoma is wide enough to pass a Robinson catheter. But a slight narrowing with irregularity is noticed above the iliosacral joint. Moderate hydronephrosis and marked dilatation of the ureter above the narrowing is still left behind.

demonstrated a normal ureter width from the stoma to the stricture site. The ureter beyond that point was still dilated, as was the pelvis. No complications were encountered over those 4 weeks. Repeated excretory urograms showed improvement in renal function. The patient's doctor reports, in answer to inquiry about the patient, that the catheter has been exchanged without any resistance or uneasiness to this date.

Case 2. A 68-year-old house-wife was admitted to the Department of Gynaecology of this hospital on October 3, 1972, with a 2-month history of persistent vaginal bleeding and discomfort in the lower abdomen. A diagnosis of 3rd-stage carcinoma of the cervix uteri was made. A week later, she referred to our outpatient clinic for examination of the upper urinary tracts. IVP's revealed bilateral moderate hydronephrosis which appeared to be due to retroperitoneal infiltration of the carcinoma.

She had received radiotherapy until November 11, when obstructive anuria developed suddenly. Three days later, IVP's revealed marked right hydronephrosis and left non-visualizing kidney, and a bilateral cutaneous ureterostomy was performed. The catheters were thereafter exchanged every two weeks at the outpatient clinic.

On January 4, 1973, after it had fallen out by itself, the left-hand catheter could be inserted only a few centimeters past the stoma. Fistulous pyelo-ureterograms revealed a stricture, 2 cm in length, located approximately 4 cm proximal to the stoma. A filiform reached the renal pelvis through the stricture, and an internal ureterotomy was completed. A Tiemann catheter has been easily inserted into the pelvis since the internal ureterotomy. No complications were encountered over the 12 weeks to this date.

DISCUSSION

Cutaneous ureterostomy, because it is simple and time-saving, has been one of the most common diversions following a radical cystectomy or a pelvic exenteration, and as a useful palliation for the ureteral obstruction due to pelvic malignancy²⁻⁵). Among all various complications that may occur subsequent to the operation, stomal stenosis is the most common in spite of many attempts to prevent the stricture. Since an indwelling catheter is the simplest way to prevent the complication, and because suitable urine collectors are difficult to obtain in this country, the patient usually has to wear indwelling catheter all his life.

However, the catheter compresses the ureter wall at the narrowest point between the stoma and the pelvi-ureteral junction, which often gradually incites peri-ureteritis at that point. This may result in stricture

sooner or later⁴⁾.

The stricture bothers both the urologist and the patient by creating various complications: difficulties in exchanging catheters, leakage of urine from the stoma, inadequate drainage of urine and infected hydro-nephrosis associated with acute febrile episode. Therefore, this condition may often require surgical revision, that is, rediversion or removal of the involved kidney unit.

The internal urethrotomy was presented by Maisonneuve in 1854 using the fixed urethrotome he devised himself. In 1872, Otis described a "dilating urethrotome", and 6 years later established the need and feasibility of cutting the anterior strictures. However, because of irrelevant conjecture as to such complications as uncontrollable hemorrhage, extravasation, perineal abscess and infection resulting in scarring and penile curvature, internal urethrotomy was virtually abandoned at the turn of the century.

In 1948, Davis and Lee⁶⁾ reported 45 cases of internal urethrotomy using the Maisonneuve urethrotome in combination with catheterization for 12 days or a sufficient period of time to permit epithelization and to prevent post-operative hemorrhage. This modification gave good long-term results. This clinic also obtained satisfactory results with a similar technique.

In 1968, Gray and Biorn⁷⁾ reported that 71 cases of urethral stricture were treated by internal urethrotomy using the Otis urethrotome and that their results were gratifying with minimal complications. In 1967, Wolf⁸⁾ presented "super Otis urethrotomy" which was performed by making repeated maximum cuts through the entire strictured urethra, including the membranous urethra and the deep cavernous tissue to the skin, usually in both anterior and posterior positions. This was done with favourable results in all of 18 patients.

Despite the series of above mentioned papers, regular dilatation remains still today the accepted standard method for treating urethral stricture. Although a method of inestimable value, it is recognized as only palliative and inadequate.

On the other hand, the internal urethrotomy is refuted by some urologists and is not widely used even for urethral strictures, much less for ureteral strictures as "internal ureterotomy". "Internal ureterotomy" has never appeared in the recent literature, but is certainly a new procedure to treat the stricture of the cutaneostomized ureter and should be attempted if a filiform can be passed through the stricture into the pelvis.

SUMMARY

“Internal ureterotomy” or a trans-ureteral cut of the stricured ureter following a cutaneous ureterostomy with an internal urethrotome was performed in a 64-year-old man and a 68-year-old woman who had received bilateral cutaneous ureterostomy and who had suffered from stricture of the ureter. This attempt gave a satisfactory results in both patients.

“Internal ureterotomy” is considered to be a new adaptation of internal urethrotomy and to be of great use.

REFERENCE

- 1) Hayashida, S., Kiriyaama, T. and Kikkawa, S.: Internal urethrotomy for strictures of the male urethra. *Acta Urologica Japonica*, 18 : 588-593, 1972. (in Japanese).
- 2) Humphreys, G.A.: Permanent cutaneous ureterostomy: A review of 174 cases. *Cancer*, 9 : 572-574, 1956.
- 3) Eckstein, H.B. and Kapila, L.: Cutaneous ureterostomy. *Brit. J. Urol.*, 42 : 306-315, 1970.
- 4) Shafik, A.: Stomal stenosis after cutaneous ureterostomy: etiology and management. *J. Urol.*, 105 : 65-70, 1971.
- 5) Feminalla, J.G., Jr. and Lattimer, J.K.: A retrospective analysis of 70 cases of cutaneous ureterostomy. *J. Urol.*, 106 : 538-540, 1971.
- 6) Davis, D. and Lee, L.W.: Lasting results following internal urethrotomy for urethral stricture. *J. Urol.*, 59 : 935-939, 1948.
- 7) Gray, C.P. and Biorn, C.L.: Internal urethrotomy: its use in the treatment of urethral strictures of the male patients. *J. Urol.*, 100 : 653-655, 1968.
- 8) Wolf, J.A., Jr.: Super Otis urethrotomy. *J. Urol.*, 97 : 713-715, 1967.