

## Tissue Adhesive Nephropexy

### Practical Utilization of Ethyl 2-Cyanoacrylate Monomer in Nephropexy

Tadao KIRIYAMA, Yoshikazu KOSHIDO,  
Norio YAMAMOTO, Kazuo NAGATA,  
Tetsuya KOJA, Yoshitaka KANEDA,  
Kazuyoshi HIRAYAMA, Mitsumasa FUJII  
and Shoji FUJISAWA

*Department of Urology, Yamaguchi University  
School of Medicine.*

(Received August 5, 1977)

### ABSTRACT

For the correction of nephroptosis a variety of surgical procedures have been devised that allow the performance of a safe and reliable operation.

Based on favorable results from previously done animal studies, tissue adhesive nephropexies were performed on 24 patients utilizing ethyl 2-cyanoacrylate monomer for the fixation of ptotic kidneys and kidneys mobilized for the performance of nephrolithotomy, pyelolithotomy or ureteropyeloplasty. It was concluded from the results of urinalysis and the patients' uneventful postoperative courses that this procedure was superior to any operation that makes use of conventional catgut suture methods.

### INTRODUCTION

Dr. Kiriya, one of the authors, previously published two papers in the Japanese language<sup>1,2)</sup> in which two series of animal studies were reported and an evaluation was made of the possible clinical applications of tissue adhesives for urological operations. In one series of studies 10 male New Zealand rabbits, weighing 2 to 2.5 kg, were treated with ethyl 2-cyanoacrylate monomer to test the bonding ability of the monomer on various types of cut surfaces. In 4 rabbits a bivalved incision of the left kidney was made while in another 5 rabbits a linear incision of the bladder wall was carried out. In the last one, a partial nephrectomy surface was covered with a free autograft of abdominal fascia for assessment of the hemostasis effect.

The pertinent results obtained are as follows:

1) None of the rabbits died during the study period. The incised surfaces all successfully bonded together. Gross examination did not reveal any evidence of hemorrhage around the bonded organs.

2) The main visceral organs were found to be unaltered upon both gross and microscopic examinations. Histological union of the wounds was perfect in both the kidneys and the bladders. Most of polymer film applied between the surfaces seemed to have been degraded in 1 to 2 weeks. The wounds appeared to have been completely reorganized in 4 to 6 weeks.

3) Roentgen examination of the bladders confirmed the bonding was complete and had sufficient strength to allow the holding of urine.

4) Small wall-attached calculi were found on the bladders of 3 of the 5 rabbits subjected to bladder bonding. Further studies demonstrated that the ethyl 2-cyanoacrylate polymer, and even the methyl 2-cyanoacrylate polymer (which is known to be absorbed slightly more rapidly than ethyl 2-cyanoacrylate polymer and thus can be applied in smaller amounts) became nidi for the production of foreign body calculi. These results suggest that regardless of the type or amount of adhesive applied to the mucosa of the bladder the polymer would serve as a nidus for calculi.

Since no test had previously been performed on bivalved human kidneys to measure the tensile strength of organ to organ monomer bonding, these results seemed to indicate that the tissue adhesive method would be most useful for fixing a mobilized or ptotic kidney. However, one more series of animal studies was carried out before a clinical trial with tissue adhesive nephropexy was started. Twentynine rats of the Wistar strain were used for this experiment. A droplet of ethyl 2-cyanoacrylate monomer was placed on the surface of the left kidney of 14 rats while a z-form suture with catgut #00 was made along the lateral margin of the left kidney of the other 15 rats. The right kidney of each animal underwent a sham operation only and served as a control.

Histological examination showed that pieces of catgut remained in the renal tissue and were surrounded by regions of acute inflammation throughout the observation period of 8 weeks. Grains of calcium were found to be deposited on every piece of catgut, and the deposits were seen to increase in severity as time went by. In contrast with these findings, the adhesive group exhibited only a slight inflammatory response in the region close to the site of adhesive application. This minimal response had almost completely disappeared within 4 weeks. Other than

these inflammatory responses there were no significant differences in the histological findings between the kidneys bonded by adhesive and the right control kidneys.

### OPERATION TECHNIQUE

Except for a few cases, the kidney was exposed extraperitoneally through a lumbar incision. After the kidney was sufficiently free to allow it to be fixed in its normal anatomical position and the upper third of the ureter was carefully liberated, the posterior surface of the kidney and the renal fossa were both prepared by removing all perirenal fat and fascia and by completing hemostasis if any bleeding was found. Once it was determined where the kidney was to be placed, the chosen area was completely sponged and a few drops of ethyl 2-cyanoacrylate monomer\* were applied at several places onto the quadratus lumborum muscle. Sometimes it was necessary to wipe water away from the application site with an instantaneous application of 90% ethyl alcohol solution. Immediately after the adhesive was applied onto the muscle the kidney was placed on it and then slightly pressed against it for approximately 5 minutes. Bonding was usually completed within 1 to 2 minutes. It should be noted that in some cases it was more convenient for the monomer to be applied to the posterior surface of the kidney.

Because the procedure of tissue adhesive nephropexy is easy, simple and reliable a sufficient bonding of the kidney to the muscle in a desirable position is almost always achieved. If bonding does not occur, it is because of one of the following reasons: 1) too much time has passed before the kidney is placed onto the muscle and the monomer has already polymerized; 2) the monomer is so old that it has already degenerated and will not work as an adhesive; or 3) there is too much water on the surface of the kidney and/or the muscle and the fluid inhibits the polymerization of the monomer.

When tissue adhesive nephropexy was carried out on a completely freed kidney following a nephrolithotomy, a pyelolithotomy or a plastic operation for obstruction at the pyeloureteral juncture, the operation was performed in exactly the same way as described above. However, on these occasions, it is essential that bleeding from the kidney and leakage of urine from the renal pelvis should be more carefully checked. With regard to recovery, the patients were made lie on their backs during the first 10 to 14 postoperative days.

---

\*Aron alpha A adhesive (ethyl 2-cyanoacrylate monomer) was supplied through the courtesy of Sankyo Co., Ltd., Tokyo, Japan.

## DISCUSSION

The tissue adhesive nephropexy procedure just described has been performed in 24 patients with gratifying results. Ten of the patients underwent the procedure after a nephrolithotomy or a pyelolithotomy, one patient after a ureteropyeloplasty. In the remaining 13 patients the operation was carried out for the original purpose of fixing a ptotic kidney.

Preoperative and postoperative excretory urograms were performed on all the patients (Fig. 1, 2). In all 13 of the patients who underwent only the nephropexy operation the ptotic kidney was pasted in, or closely to, a normal anatomical position (Fig. 1), whereas in most of the other 11 patients, the kidney tended to be fixed below the normal anatomical position (Fig. 2). The reason for the discrepancy in the procedures is that in the cases involving either the removal of a kidney stone or the correction of a narrowed pyeloureteral juncture, these surgical procedure were the primary concern and the fixation of the kidney was of only secondary importance. In such cases, less effort was made to suspend

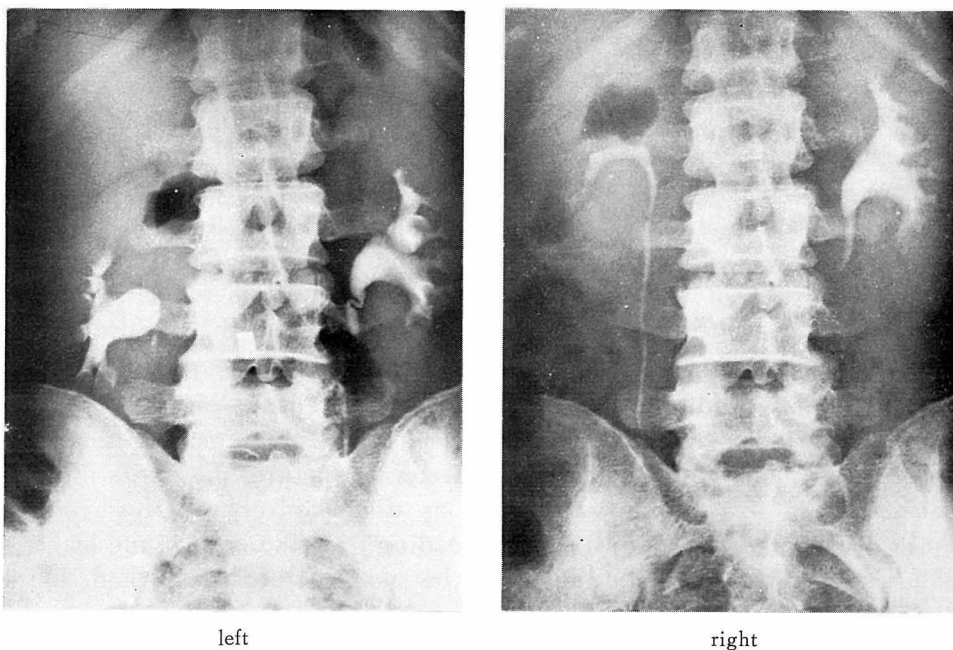


Fig. 1. Excretory urograms before (left) and after (right) a bilateral tissue adhesive nephropexy. In upright position. There is a marked descent of the right kidney on the preoperative film. The postoperative film reveals the kidney is now at a normal level.

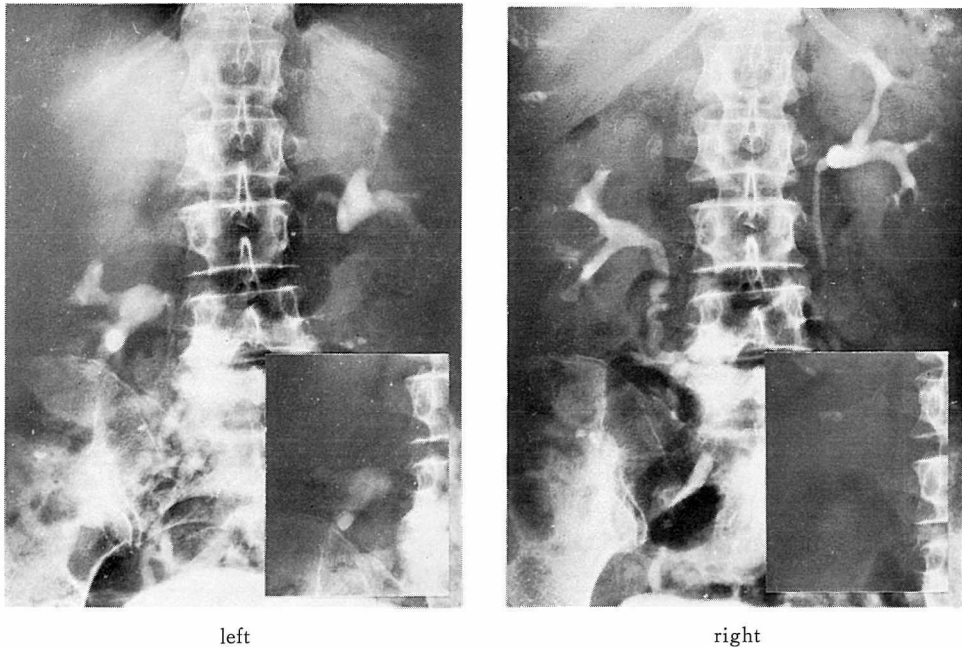


Fig. 2. Plain films and excretory urograms before (left) and after (right) a right pyelolithotomy and a right tissue adhesive nephropexy. In upright position. The postoperative film shows that the kidney was fixed in a slightly lower than optimum position. An irregular-shaped calcific shadow overlying the right upper renal area on the postoperative plain film is identical to the extrarenal shadow on the excretory urogram.

the kidney in the most advantageous position.

The technique of tissue adhesive nephropexy offers several distinct advantage over conventional methods. It reduces operative time by reducing the number of operative steps. Also, we believe that this procedure does less damage to the kidney than other kinds of nephropexy. The animal studies we performed prior to the clinical trial, and which were mentioned earlier in this paper, are evidence for such a conclusion. This conclusion was further corroborated by a comparison of the results of urinalysis of the first six consecutive patients who underwent the tissue adhesive nephropexy and 4 other patients who received Kelly-Dodson's nephropexy during the same period (Fig. 3). However, the most distinct advantage is that the adhesive technique is the easiest and the most reliable method of fixing a ptotic kidney in an optimal position.

In animal studies and in a few studies in humans, a variety of cyanoacrylate monomers such as methyl, ethyl, N-butyl and is O-butyl cyanoacrylate have been utilized in the kidney for hemostasis during polar

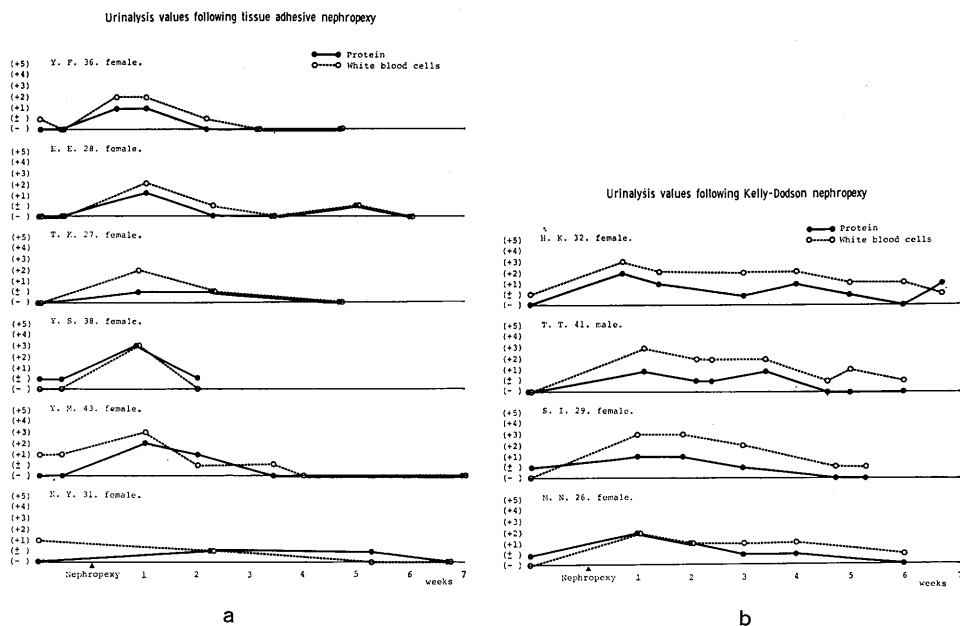


Fig. 3. Urine examinations showed that the kidneys that received Kelly-Dodson nephropexy seemed to take a longer time to recover than those which received tissue adhesive nephropexy.

amputation, wedge resection, nephrotomy and renal trauma and also for the special cases of ureteral anastomosis and closure of bladder wounds<sup>3-11</sup>). Encouraging results with regard to the hemostasis and the closure of the wounds were reported in almost all the papers. However, scar formation, calcification and foreign body granuloma were noted in the tissue. Because tissue adhesive nephropexy involves application of the monomer to the outside surface of the kidney only it avoids the complications of scar formation, calcification and foreign body granuloma, and the prolonged polymerization time of ethyl 2-cyanoacrylate monomer is also an advantage for nephropexy, although disadvantageous for hemostasis. Thus, tissue adhesive is a very convenient material for completing a desirable nephropexy.

## REFERENCES

- 1) Hongo, H. and Kiriya, T.: Studies on cyanoacrylate adhesives in the field of urology. I. Adhesion of incised wound surface of the kidney and incised wound edge of the bladder of rabbit. *Acta Urol. Jap.*, 10 : 617-625, 1964, (Japanese).
- 2) Sakatoku, J., et al.: Studies on cyanoacrylate adhesives in the field of urology. II. Application of the adhesives for nephropexy. *Acta Urol. Jap.*, 11 : 250-258, 1965, (Japanese).
- 3) Just-Viera, J.O., del Aguilla, R.P. and Yeager, G.H.: Experimental control of renal hemo-

- rrhage with the use of polymerizing adhesives. *Surgery*, 55 : 531-543, 1964.
- 4) Mathes, G.L., Mayer, W. and Raines, S.L.: Plastic adhesive closure of nephrotomy. *Southern Med. J.*, 57 : 1071-1074, 1966.
  - 5) Mathes, G.L. and Terry, J.W., Jr.: Non-suture closure of nephrotomy. *J. Urol.*, 89 : 122-125, 1963.
  - 6) Matsumoto, T.: Vienna international symposium-Tissue adhesives in surgery. *Arch. Surg.*, 96 : 226-230, 1968.
  - 7) Matsumoto, T., et al.: N-alkyl- $\alpha$ -cyanoacrylate monomers in surgery. *Arch. Surg.*, 94 : 153-156, 1967.
  - 8) Matsumoto, T., et al.: Higher homologous cyanoacrylate tissue adhesive in injured kidney. *Arch. Surg.*, 94 : 392-395, 1967.
  - 9) Truss, F., et al.: Improved technique of non-suture closure of renal wounds. *J. Urol.*, 95 : 607-612, 1966.
  - 10) Wojnar, V.S., et al.: Liver, spleen, and kidney wounds. Experimental repair with topical adhesive. *Arch. Surg.*, 89 : 237-243, 1964.
  - 11) Yoho, A.V., et al.: Experimental evaluation of tissue adhesives in urogenital surgery. *J. Urol.*, 92 : 56-59, 1964.