

Bull Yamaguchi Med Sch 44(1-2) : 11-19, 1997

Hemodynamics in Patients with Hypertensive Intracerebral Hemorrhage

Tetsuhiro Kitahara

Department of Neurosurgery, Yamaguchi University School of Medicine
(Received March 28, 1977, revised July 22, 1997)

Abstract Cerebral hemodynamics in 15 patients with hypertensive intracerebral hemorrhage (HICH) were evaluated by measuring cerebral blood flow (CBF) and cerebrovascular reserve capacity, using stable xenon-enhanced computed tomography. Their hematomas were removed by stereotactic aqua stream aspiration. The hemispheric and thalamic CBFs of patients with HICH were lower than those of hypertensive patients without hematomas. However, the hemispheric CBF increased according to how much of the hematoma was removed surgically. Thus, hemodynamics in patients with HICH can be improved by surgical hematoma removal, although some adjunct therapies are necessary in order to prevent secondary edema and the delayed neuronal death.

Key words : hypertensive intracerebral hemorrhage, cerebral blood flow, Xe-CT, acetazolamide

Introduction

Hypertensive intracerebral hemorrhage (HICH) is a significant cause of morbidity and mortality in Japan. The mortality of patients with HICH has decreased due to progress in medicine, for example, anti-hypertensive drugs and medical care, but morbidity remains high.

Surgical procedures for HICH are controversial. Cushing evacuated HICH by the large craniotomy in 1902²⁾. Nowadays, stereotactic surgery, a less invasive approach would be selected¹⁰⁾, and various stereotactic methods, such as computed tomography (CT)-guided evacuation¹¹⁾ and aqua stream aspiration^{3,4)} have been reported to be effective²⁰⁾.

Recently, positron emission tomography (PET), single photon emission computed tomography (SPECT) and xenon-enhanced computed tomography (Xe-CT) have been

used to evaluate the hemodynamics and/or metabolism of the brain. Cerebral blood flow (CBF) can be estimated by Kety and Schmidt's method using Xe-CT⁸⁾, the advantages of which are that it is easy, repeatable and quantitative.

Arteriolar endothelial cells become acidotic in response to acetazolamide, a so-called carbonic anhydrase inhibitor, which causes cerebral arterioles to dilate¹⁸⁾. The acetazolamide test is very useful for assessing hemodynamics in patients with cerebrovascular disease^{12,19)}, but, as far as I am aware acetazolamide-loaded CBF measurements in patients with HICH have not been reported⁹⁾.

The author used Xe-CT to study cerebral hemodynamics in patients with hypertensive intracerebral hemorrhage.

Methods of clinical studies

CBF was measured in 15 patients with HICH (8 males and 7 females aged 44 to 83 years, mean 61.7), 11 hypertensive patients without HICH (aged 60 to 77 years, mean 68.5) and 20 normal volunteers (aged 23 to 73, mean 44.6). The hematomas of all the HICH patients were evacuated by stereotactic aqua stream aspiration through a burr hole, under local anesthesia, within a week of the intracerebral hemorrhage. The preoperative hematoma volume (V) was calculated using the following formula (I), in which L, W and H are the length, width and height of the hematoma, respectively, on the CT images:

$$V = 1/2L \times W \times H \dots\dots\dots (I)$$

The CBFs of 9 patients were measured at the chronic stage. Stable Xe-CT CBFs were measured using a SOMATOM DR3 CT scanner with software for CBF imaging (Siemens Medical Systems, Erlangen, Germany). A XETRON 3 closed circuit inhalator (Anzai Sogyo Ltd., Tokyo, Japan) was used to supply xenon gas. After two baseline CT scans, each

subject inhaled a 30% xenon/30% oxygen/40% nitrogen gas mixture for 3 min through a face mask, using a 3-min wash-in/3-min wash-out inhalation protocol method⁶⁾, and CT scanning was performed every minute for 6 min. After measuring the resting CBF, an arterial blood sample was taken to measure the oxygen and carbon dioxide partial pressures, pH, base excess, and hematocrit. Then, each patient received acetazolamide 17 mg/kg administration intravenously, and CBF measurement and arterial blood sampling were repeated. The cerebrovascular reserve capacity (CRC) was defined as the difference between the acetazolamide-induced CBF and resting CBF. The regions of interest (ROIs) in the hemisphere and thalamus, except that of the hematoma itself, and those around the hematoma at the acute stage were selected voluntarily (Fig.1A,B).

The values are expressed as means and standard deviations. An unpaired t-test was used to compare the data for the HICH and non-hemorrhagic hypertensive patients, and a paired t-test was used to compare perioper-

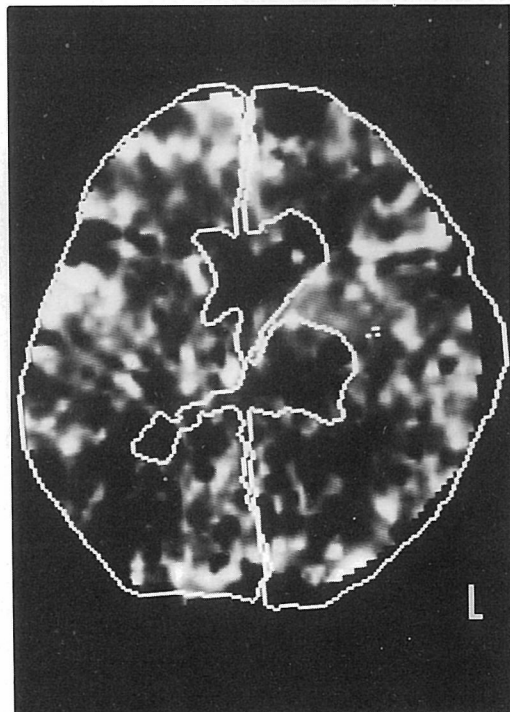


Fig 1A

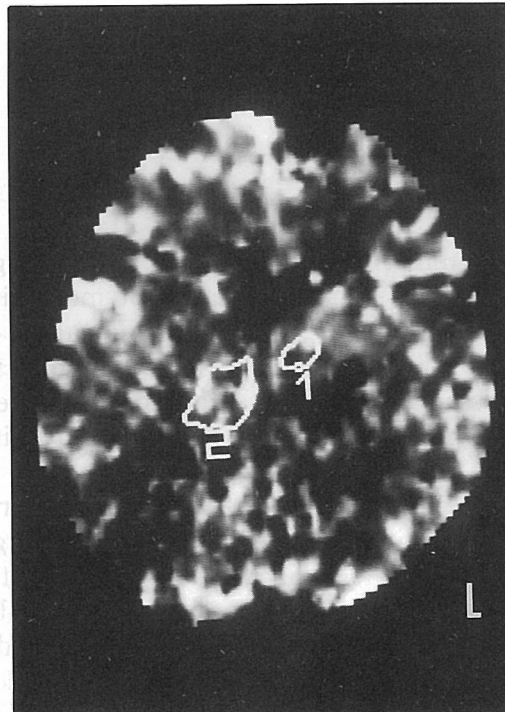

Fig. 1B

Fig. 1. Voluntarily selected regions of interest (ROIs). A : ROIs in the hemispheres contralateral and ipsilateral to the hematoma, except that of the hematoma itself, were selected voluntarily. B : ROIs on contralateral and ipsilateral sides of the thalamus except that of the hematoma itself, were selected voluntarily.

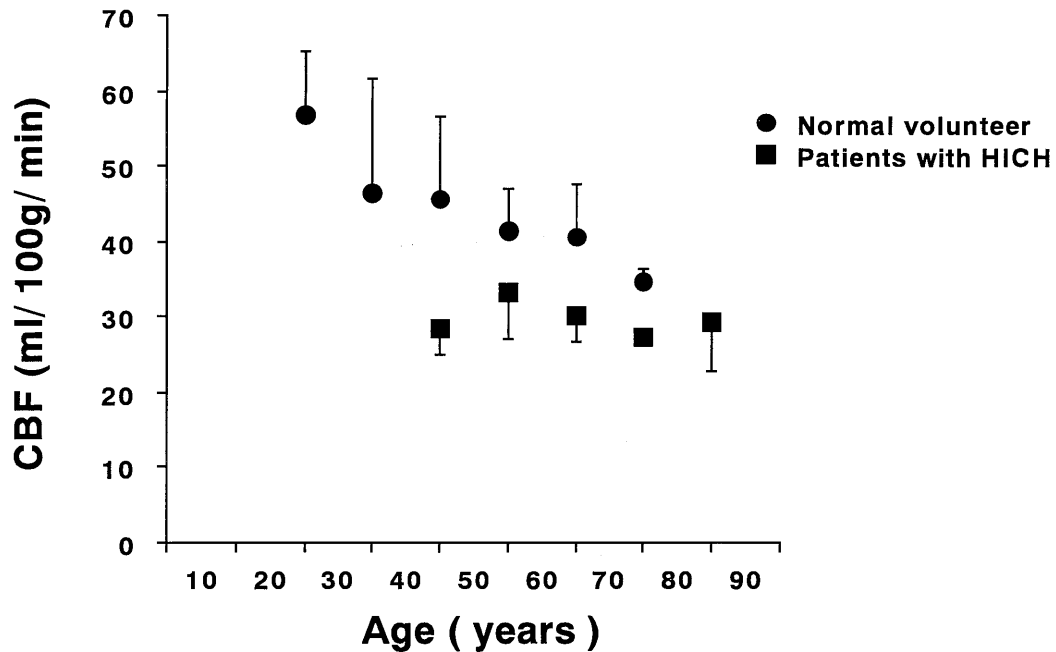


Fig. 2. Relationship between age and hemispheric CBF in normal volunteers, and CBFs of age-matched patients with HICH. Ordinate : CBF ; abscissa: age ; circles : CBF of normal volunteers ; squares: CBF of patients with hypertensive intracerebral hematoma (HICH) ; bars : standard errors.

ative data for the same patients. Differences at $p < 0.05$ were considered significant. Pearson's correlation coefficient was used to determine the relationship between residual hematoma volume and CBF.

Results

Relationship between CBF and age :

The mean CBF of the young volunteers was higher than that of the older volunteers (Fig. 2), and CBF declined gradually with age. The mean CBF of the patients with HICH was lower than that of the age-matched normal volunteers.

CBF in the acute stage :

In the acute post HICH stage, CT images of a 61-year-old woman with a left thalamic hemorrhage showed a hematoma with a volume of 15ml. The hemispheric CBFs on the hemorrhagic and non-hemorrhagic sides were 35.1 and 38.1ml/100g/min, respectively, and the respective thalamic CBFs were 38.7 and 44.5ml/100g/min (Fig.3).

Preoperative and postoperative CBFs were measured in 6 patients with HICH. The mean hemispheric CBF on hemorrhagic side in-

creased significantly after hematoma evacuation (Fig.4A), but the pre- and postoperative thalamic CBFs did not differ significantly (Fig.4B). The pre- and postoperative hemispheric CRCs did not differ significantly (Fig. 5A), whereas the thalamic CRC appeared to increase, but not to a significant extent (Fig. 5B).

The CBF within 2cm of the hematoma border did not increase after surgery, but after evacuation, the CBF over 2cm from the border did increase significantly (Fig.6).

CBF in the immediate postoperative stage :

Seventy per cent of the hematoma was removed, and a drainage tube was inserted into the hematoma cavity. The hemispheric CBFs on the hemorrhagic and non-hemorrhagic sides were 46.8 and 47.3ml/100g/min, respectively, and the respective thalamic CBFs were 62.9 and 77.7ml/100g/min. Therefore, removal of the hematoma increased the CBF.

CBF in the chronic stage :

The mean hemispheric and thalamic CBFs on the hemorrhagic side of 9 patients with HICH at the chronic stage were significantly

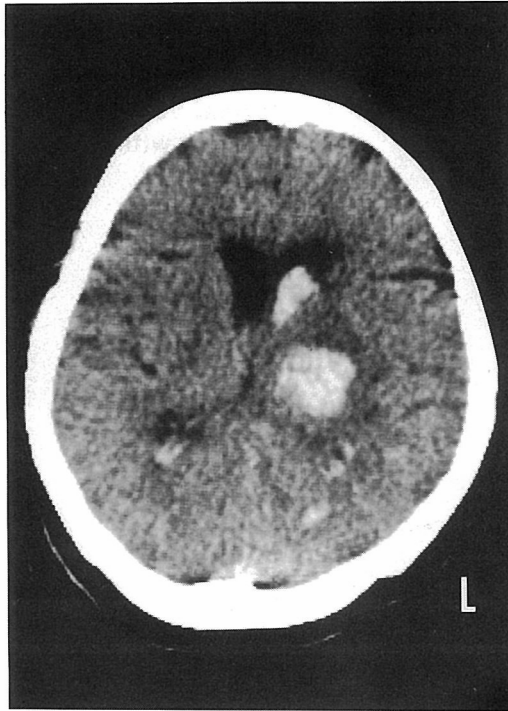


Fig. 3A

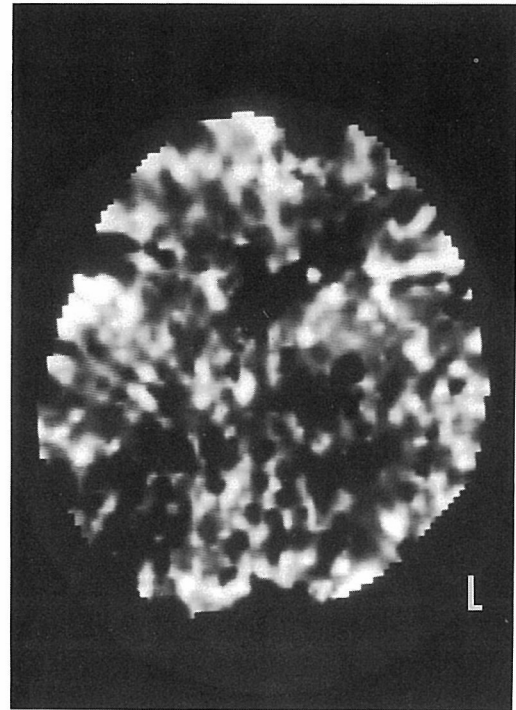


Fig. 3B

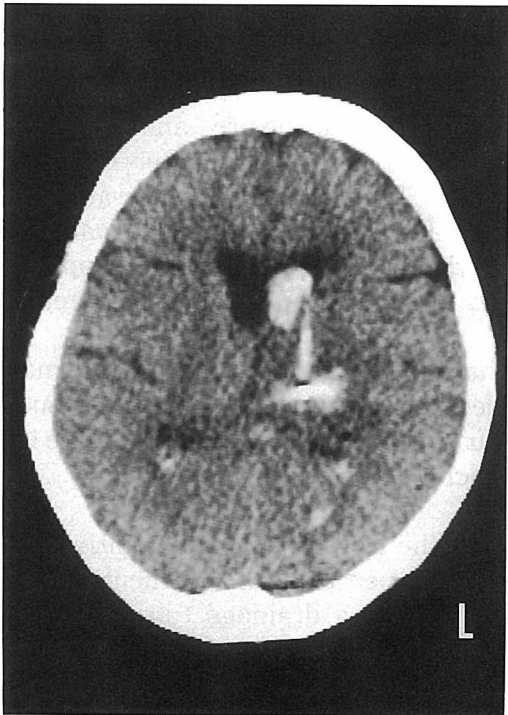


Fig. 3C

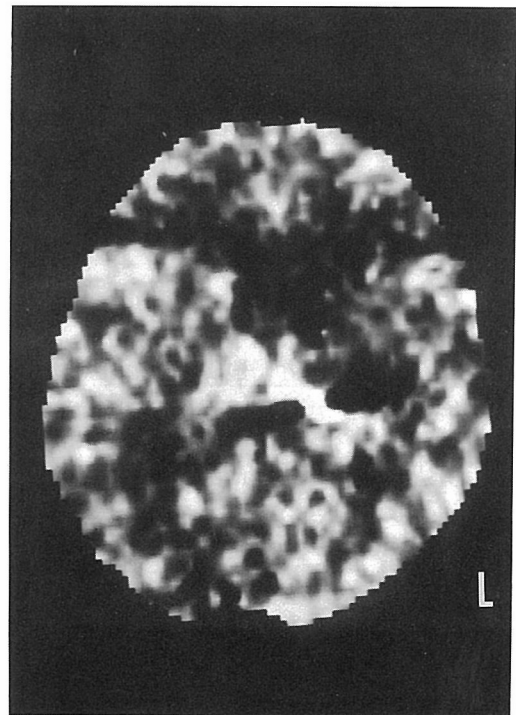


Fig. 3D

Fig. 3. CT images of a 61-year-old woman with left thalamic bleeding. A : Preoperative CT image showing thalamic bleeding with perifocal edema and bleeding in the bilateral lateral ventricles. B : Preoperative Xe-CT. The white areas indicate high CBFs, and the darker ones low CBFs. The CBF is reduced in the hemorrhagic area compared with the non-hemorrhagic area. C : Postoperative CT image showing partial removal of the hematoma and a drainage tube in the hematoma cavity. D : Postoperative Xe-CT. The CBFs of the ipsilateral hemisphere and bilateral thalamus increased after surgery in comparison with those before.

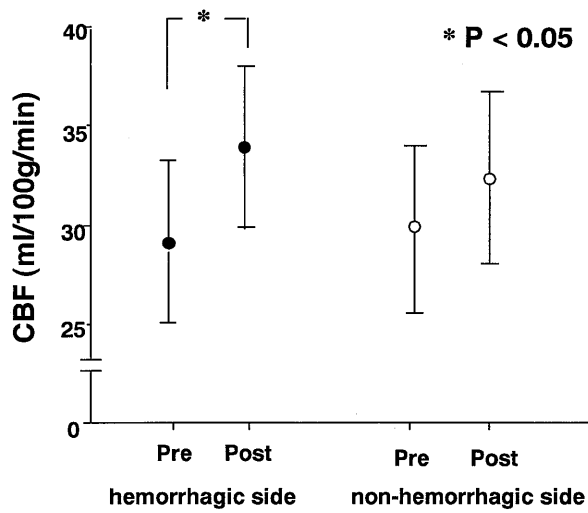


Fig. 4A

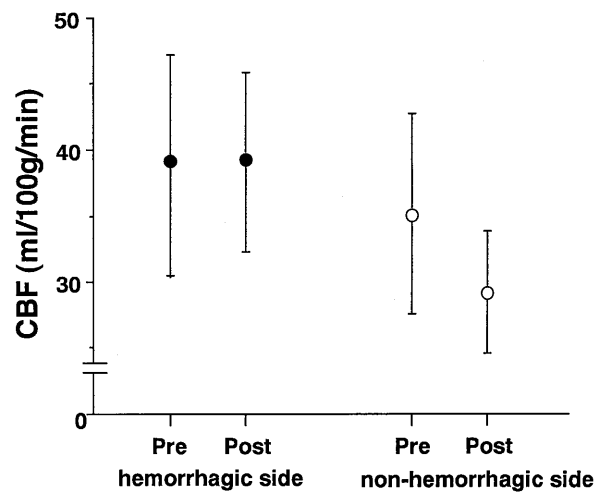


Fig. 4B

Fig. 4 (A,B). Mean perioperative hemispheric and thalamic CBFs. Solid and open circles show the mean hemorrhagic and non-hemorrhagic side values, respectively, and the bars are standard deviations. Abbreviations: CBF, cerebral blood flow; Pre, preoperative stage; post, postoperative stage. A: Perioperative hemispheric CBF. The hemispheric CBF on the hemorrhagic side increased significantly after hematoma evacuation. B: Perioperative thalamic CBF. There was no significant differences between the pre- and postoperative values.

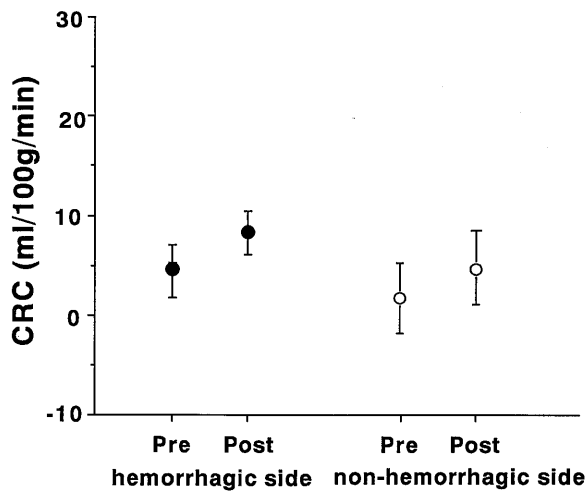


Fig. 5A

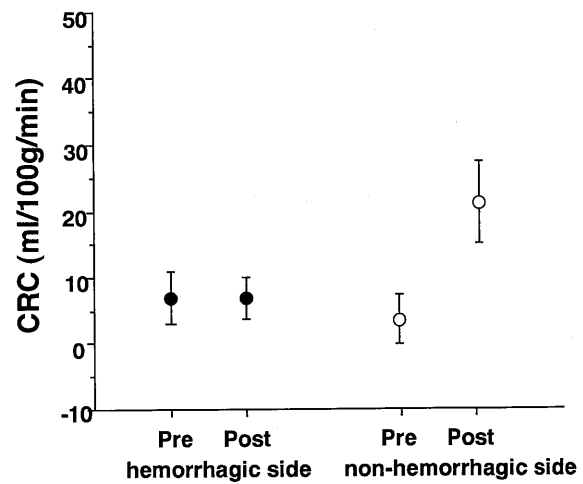


Fig. 5B

Fig. 5 (A,B). Mean hemispheric and thalamic cerebrovascular reserve capacities (CRCs). A: The hemispheric CRCs before and after hematoma evacuation did not differ significantly. B: The postoperative thalamic CRC appeared to increase compared with the preoperative value, but the difference was not significant. Solid and open circles show the CRCs on the hemorrhagic and non-hemorrhagic sides, respectively.

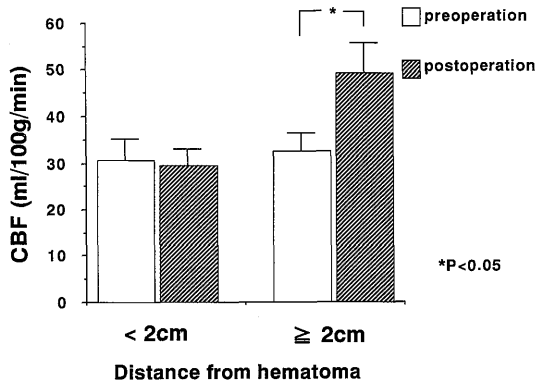


Fig. 6. Relationship between CBF and the distance from the hematoma border during the perioperative period. The CBF over 2cm from the hematoma border increased significantly after evacuation of the hematoma.

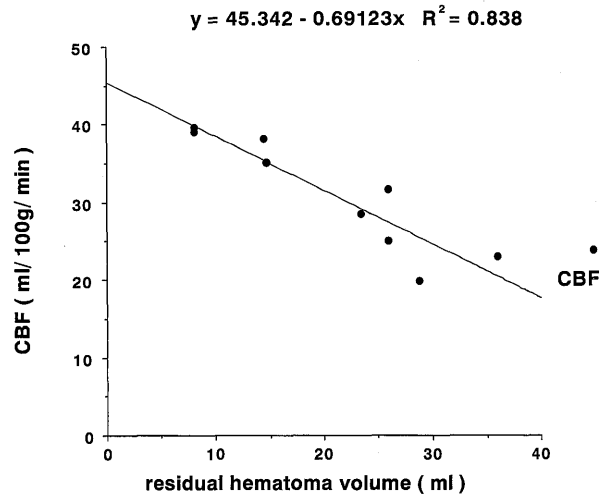


Fig. 9. Relationship between residual hematoma volume and CBF. The greater the residual hematoma volume, the greater the reduction of the CBF. There was a significant inverse relationship ($Y = 45.342 - 0.69123 X, R^2 = 0.838, p < 0.01$). Ordinate: hemispheric CBF on the hemorrhagic side; abscissa: residual hematoma volume, R^2 : coefficient of multiple determinations.

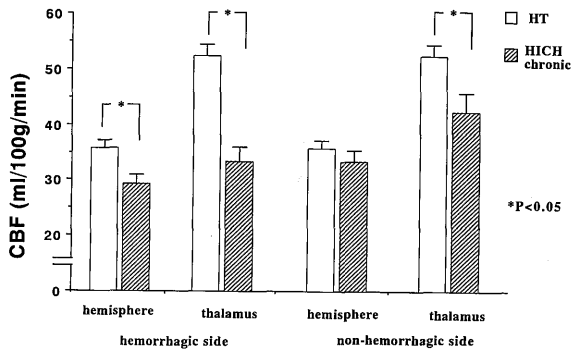


Fig. 7. CBFs of hypertensive patients with and without HICH. The mean CBFs on the hemorrhagic side of those with HICH were significantly lower than that of those without hematomas. Abbreviations: HT, hypertensive patient; HICH, hypertensive intracerebral hemorrhage.

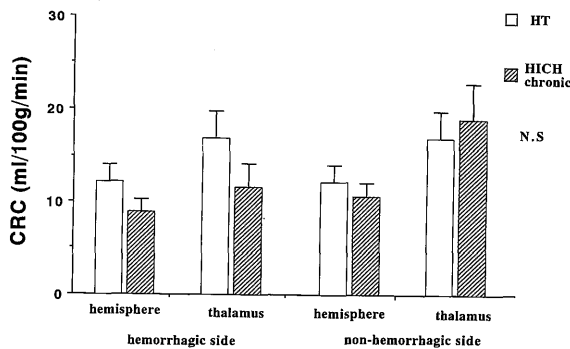


Fig. 8. CRCs of hypertensive patients with and without hematomas. There were no significant differences between the two groups.

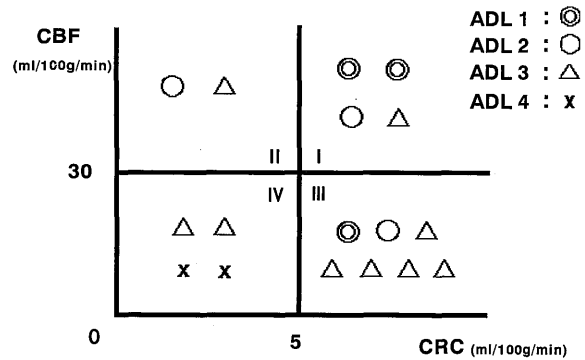


Fig. 10. Relationship between cerebral hemodynamics and activities of daily life of patients with HICH. Fifteen patients with HICH were classified into 4 groups as the border of value in 30ml/100g/min of CBF and 5ml/100g/min of CRC. Double circles: ADL 1 (almost normal life); circles: ADL 2 (moderately disabled); triangles: ADL 3 (severely disabled); crosses: ADL 4 (bedridden). The ADL scores tended to be higher when the CBFs were 30ml/100g/min or lower and/or the CRCs were 5ml/100g/min.

lower than those of the 11 hypertensive patients without hematomas (Fig.7). The mean thalamic CBF on the non-hemorrhagic side of the hypertensive patients with HICH was significantly lower than that of those without HICH. The mean CRCs of these two groups did not differ significantly (Fig.8).

Relationship between CBF and residual hematoma volume after surgery :

The greater the volume of hematoma remaining after evacuation, the greater the reduction of the CBF (Fig.9).

Relationship between the cerebral hemodynamics and activities of daily life of patients with HICH :

The relationship between the cerebral hemodynamics and activities of daily life (ADL) of the patients with HICH is shown in Fig.10. The patients were classified into 4 groups according to their CBF and CRC values, following using Yamashita's modified classification¹⁹⁾.

Discussion

A few clinical^{1,3)} and experimental^{13,14)} studies of the hemodynamics associated with HICH have been carried out. Generally, the CBF of patients with HICH, is lower than that of healthy adults^{1,3)}, Nath et al. reported that the CBF of rats declined within 1 min of cerebral bleeding¹³⁾. The CBF of humans usually declined gradually with age¹⁵⁾, and our data showed that the CBF of patients with HICH was lower than that of age-matched normal volunteers.

At the chronic stage of HICH, the hemodynamics should be stable. The mean CBF of patients with chronic-stage HICH was lower than that of the hypertensive patients without hematomas in this study. The CBF was reduced by cerebral bleeding, which did not affect the CRC significantly.

Sequential CBF measurements in patients with HICH showed that CBF increased after hematoma removal. There are few reports of CBF increases in patients with HICH at the immediate postoperative stage, although the CBF was found to be reduced after the acute stage^{9,20)}. It declined gradually in a month

after intracerebral hemorrhage⁹⁾, reached the nadir two months after intracerebral hemorrhage and increased thereafter²⁰⁾. CT imaging showed the hematomas disappeared in 3-4 weeks. Cerebral hemodynamics are affected by various factors, such as direct destruction of neuronal tissue, vascular compression by the hematoma and surrounding edema¹⁷⁾. The greater the residual hematoma volume, the greater the reduction of the CBF. Therefore, as much of a hematoma as possible should be removed from the viewpoint of the CBF, but, removal of 70-80% would be usually the goal to reduce the risk of rebleeding, which may increase the CBF further.

The CBF over 2cm from the hematoma border increased significantly. After hemorrhage into the brain, direct destruction of brain tissue and vascular compression are caused by the hematoma and edema, and these effects are more severe near the hematoma. However, 2cm or further away, the damage is less severe and hematoma removal leads to reduction of the compression.

Generally, the ADL of patients with HICH are thought to depend on the hematoma location. However, from the viewpoint of hemodynamics, the ADL categories of the patients with high CBF and CRC values were lower, i. e. they were less disabled, than those with low CBFs and CRCs. Yoshinaga et al. reported that a low CBF was associated with a poor ADL score and that the thalamic CBF affected mental activity²⁰⁾.

The CRC is a useful indirectly estimated marker of peripheral perfusion pressure for studying ischemic cerebrovascular disease. There is little information about CRC in patients with HICH. The CRC of patients with HICH was found to decline in the acute stage and improved gradually thereafter⁹⁾. Hematomas cause vascular compression and sometimes the CBF is reduced in a diffuse pattern in patients with HICH at the chronic stage, but the CRC remains normal. This would account for the poor perfusion caused by cerebral hypometabolism, such as neuronal inactivity and/or transneuronal depression. The latter results from destruction of the neuronal fibers by hematomas and anatomical examination revealed that cortico-striate and thalamo-striate neuronal connections were

often destroyed by hematomas¹⁶⁾. Therefore, regions where the CRC is not reduced can be expected to recover their function and some drugs, such as metabolic activators, may be useful for promoting such recovery. Administration of basic fibroblast growth factor and neuro-protective chemical substances, into the hematoma cavities of rats prevented delayed neuronal damage, demonstrated histologically, in the hippocampus⁷⁾. The clinical application of such substances is expected to be investigated in clinical trials in the near future.

Conclusions

CBF was measured in patients with HICH, hypertensive patients without hematomas and normal volunteers. The CBF was increased by hematoma removal, particularly in areas where direct neuronal damage was less severe, over 2cm from the hematoma border. As much of a hematoma as possible should be removed, because the CBF increased more the more of a hematoma was removed. After hemorrhage into the brain, the CBF declines due to direct neuronal damage and vascular compression by the hematoma. Sequential measurement of the CRC in patients with HICH showed it was not affected significantly by hematoma evacuation.

Acknowledgements

The author wishes to thank Professors Haruhide Ito and Naofumi Matsunaga, Departments of Neurosurgery and Radiology, respectively, Yamaguchi University, and Drs Tetsuo Yamashita and Shiro Kashiwagi, Department of Neurosurgery, Yamaguchi University, for their useful advice.

References

- 1) Agnoli A., Fieschi C., Prencipe M., Battistini N., and Bozzao L. : Relationships between regional hemodynamics in acute cerebrovascular lesions and clinico-pathological aspects. in Meyer J.S., Reivich M., Lechner H., Eichhorn O. (eds.), *Research on the cerebral circulation, Fourth International Salzburg Conference*, Springfield, CC Thomas, 1970, pp. 148-154.
- 2) Cushing H. : Some experimental and clinical observations concerning states of increased intracranial tension. *Am J Med Sci*, **124** : 375-400, 1902.
- 3) Ishii R., Takeuchi S., Ohsugi S., Tanaka R., and Arai H. : Cerebral blood flow in patients with putaminal hemorrhage. *Neuro Med Chir (Tokyo)*, **22** : 813-821, 1982.
- 4) Ito H., Mukai H., Kitamura A., and Yamashita J. : Stereotactic aqua stream and aspirator for hypertensive intracerebral hematoma. *Stereotact Funct Neurosurg*, **53** : 77-84, 1989.
- 5) Iwamoto N., Kusaka M., Tsurutani T., Kameda H., and Ito H. : Ultrasound imaging for stereotactic evacuation of hypertension-associated intracerebral hematomas with aqua-stream and aspiration. *Stereotact Funct Neurosurg*, **60** : 194-204, 1993.
- 6) Kashiwagi S., Yamashita T., Nakano S., Kalender W., Polacin A., Takasago T., Eguchi Y., and Ito H. : The wash-in/washout protocol in stable xenon CT cerebral blood flow studies. *Am J Neuroradiol*, **13** : 49-53, 1992.
- 7) Kawakami N., Kashiwagi S., Kitahara T., Yamashita T., and Ito H. : Effect of local administration of basic fibroblast growth factor against neuronal damage caused by transient intracerebral mass lesion in rats. *Brain Res*, **697** : 104-111, 1995.
- 8) Kety S.S. and Schmidt C.F. : The determination of cerebral blood flow in man by use of nitrous oxide in low concentration. *Am J Physiol*, **143** : 53-66, 1945.
- 9) Kitahara T., Yamashita T., Kashiwagi S., Kawakami N., Ishihara H., and Ito H. : Hemodynamics of hypertensive putaminal hemorrhage evaluated by xenon-enhanced computed tomography and acetazolamide test. *Acta Neurol Scand, Suppl*, **166** : 139-143, 1996.
- 10) Leksell L., and Jernberg B. : Stereotaxis and tomography : A technical note. *Acta Neurochir*, **52** : 1-7, 1980.
- 11) Matsumoto K., and Hondo H. : CT-guid-

- ed stereotaxic evacuation of hypertensive intracerebral hematomas. *J Neurosurg*, **61** : 440-448, 1984.
- 12) Nariai T., Suzuki R., Hirakawa K., Maehara T., Ishii K., and Senda M. : Vascular reserve in chronic cerebral ischemia measured by the acetazolamide challenge test : Comparison with positron emission tomography. *Am J Neuroradiol*, **16** : 563-570, 1995.
- 13) Nath F.P., Jenkins A., Mendelow A.D., Graham D.I., and Teasdale G.M. : Early hemodynamic changes in experimental intracerebral hemorrhage. *J Neurosurg*, **65** : 697-703, 1986.
- 14) Nehls D.G., Mendelow A.D., Graham D.I., Sinar E.J., and Teasdale G.M. : Experimental intracerebral hemorrhage : Progression of hemodynamic changes after production of a spontaneous mass lesion. *Neurosurgery*, **4** : 439-444, 1988.
- 15) Pantano P., Baron J.C., Lebrun-Grandie P., Duquesnoy N., Boussier M.G., and Comar D. : Regional cerebral blood flow and oxygen consumption in human aging. *Stroke*, **15** : 635-641, 1984.
- 16) Sugiyama H. : Cerebral blood flow in patients with hypertensive intracerebral hemorrhage : With regard to differences in the mechanism of flow reduction between putaminal and thalamic hemorrhage. *Neurol Med Chir (Tokyo)*, **24** : 564-572, 1984.
- 17) Tazawa T., Mizukami M., Kawase T., and Usami T. : The relationship between intracranial pressure and regional cerebral blood flow in hypertensive intracerebral hemorrhage. *J Cereb Blood Flow Metab*, **1** (Suppl 1) : S545-S546, 1981.
- 18) Vorstrup S., Henriksen L., and Paulson O. B. : Effect of acetazolamide on cerebral blood flow and cerebral metabolic rate for oxygen. *J Clin Invest*, **74** : 1634-1639, 1984.
- 19) Yamashita T., Kashiwagi S., Nakano S., Takasago T., Abiko S., Shiroyama Y., and Ito H. : The effect of EC-IC bypass surgery on resting cerebral blood flow and cerebrovascular reserve capacity studied with stable Xe-CT and acetazolamide test. *Neuroradiology*, **33** : 217-222, 1991.
- 20) Yoshinaga S. : Sequential changes of cerebral blood flow in hypertensive putaminal hemorrhage (in Japanese). *No-Shinkeigeka*, **22** : 223-229, 1994.